



# International Journal of Scientific Research in Dental and Medical Sciences

www.ijstdms.com



## Microbiological Profile of Post-COVID-19 Mucormycosis in Various Samples

Sirisha Munipati, Hymavathi Rachamadugu\*, Surekha Avileli, Renuka Avula, Naga Jyothi Beladona, Shanthi Reddy Boyapally

Department of Microbiology, Kurnool Medical College, Kurnool, India

### ARTICLE INFO

#### Article history:

Received 18 April 2022

Received in revised form 31 May 2022

Accepted 12 June 2022

Available online 15 June 2022

#### Keywords:

Infections

Mucor

Rhizopus

SARS-CoV-2

### ABSTRACT

**Background and aim:** Increase in fungal superinfections among post-COVID-19 patients created a panic during pandemic times in India. Rhino-orbital mucormycosis cases have seen a rise in India among COVID-19 patients. This study aims and objectives to know the Incidence of Mucormycosis among COVID-19 infected patients and the age and sex distribution of Post COVID-19 Mucormycosis patients.

**Material and methods:** All clinical specimens were received at the Microbiology department from respective hospital units in sterile normal saline leak-proof containers. Fungal cultures were followed until growth occurred or till 28 days. Macroscopic and microscopic characteristics identified positive culture fungal growth.

**Results:** Out of 97 post covid fungal infection patients in this study, 33 (34.02%) were female, and 64 (65.9%) were male. Predominant populations were in the age group of 41 - 60; it was 60 out of 97 (61.8%), followed by 61-71 years (24.7%). Out of 97 fungal pathogens, Mucor, Aspergillus, and Mucor fungi were isolated predominantly; it was 32 (32.9%), 29 (29.8%), 16 (16.4%), and 11 (11.3%), respectively.

**Conclusions:** Early Diagnosis and treatment will help manage SARS-CoV-2-associated fungal infections. The formulation of stringent infection control protocols, antimicrobial usage policy, and updated COVID-19 management guidelines by government authorities helps reduce infections.

### 1. Introduction

Severe acute respiratory syndrome coronavirus 2 (SARS-CoV-2) virus was previously designated as the 2019 novel coronavirus (2019-nCoV)<sup>[1]</sup> that belongs to corona variants. It is a single-stranded positive-sense RNA virus that is responsible for the COVID-19 pandemic; the virus has been confirmed as human-to-human transmission. On December 1, 2019, the earliest case of COVID-19 infection was noted, although there may be a few cases that could have occurred before this date.<sup>[2]</sup> SARS-CoV-2 or novel coronavirus could be associated with secondary infections due to misuse of antibiotics in many health care centres, irrational antibiotic prescription in many countries, especially in low and middle-income countries, widespread antibiotic usage in hospital settings due to an increase in the longevity of Immunocompromised patients, widespread antibiotic use in veterinary settings and animal husbandry. After a few weeks of SARS-CoV-2 infection, if the patient had health issues related to the post effects of COVID-19, such patients were referred to as "Post-COVID-19 patients". Post COVID-19 syndrome, or long COVID-19, is a condition in which patients who have been affected by COVID-19 experience symptoms that continue even after their initial recovery. Post-COVID-19 symptoms include fever, chest pain, cough, SOB, muscle and joint pains, memory loss, depression, smell or taste, and difficulty breathing. There is a great need to closely monitor COVID-19-

affected patients to check how their organs function after initial recovery.<sup>[3]</sup> SARS-CoV-2 can present as an asymptomatic stage or a mild to life-threatening pneumonia picture. Fungal co-infections have been noted in COVID-19 infected patients. There were many predisposing factors for fungal co-infections/superinfections, such as co-morbidities including Diabetes Mellitus, COPD, Sinusitis, previous lung pathologies, immunosuppressive therapy, or risk of nosocomial infections or attenuation in the immune system due to SARS-CoV-2 infection.<sup>[4]</sup> Rhino-orbital mucormycosis cases have seen a rise in India among COVID-19 patients. It is a rare, fatal, invasive fungal infection that originates in the paranasal sinuses and may frequently extend into the orbits and cerebral parenchyma.<sup>[5]</sup> An increase in super fungal infections among post-COVID-19 patients created a panic during pandemic times in India. Clinical manifestations of fungal sinusitis may not provide clear differentiation from other infections pathology; clinical diagnosis needs to be strengthened by laboratory and imaging services for prompt diagnosis. Fungal infections can be diagnosed by staining techniques, culture, serological methods, and imaging modalities. This hospital is a government medical college serving as a dedicated COVID-19 hospital since the COVID-19 pandemic began. We want to share the data to help health authorities and clinicians manage COVID-19 patients. We tried to protect the data from the community and clinicians, which may help

\* Corresponding author. Hymavathi Rachamadugu

E-mail address: hymavathir41@gmail.com

Department of Microbiology, Kurnool Medical College, Kurnool, India

<http://doi.org/10.30485/IJSDMS.2022.338567.1285>



manage patients and early diagnosis. This study aims to determine the incidence of mucormycosis among COVID-19 infected patients and the age and sex distribution of post-COVID-19 mucormycosis patients.

## 2. Material and methods

### Ethical approval

The ethics committee approved the study proposal of the College of the Kurnool Medical College, Kurnool, India. Informed written consent was obtained from all the participants before sample collection.

A prospective, descriptive, cross-sectional study was designed and conducted at the Department of Microbiology, Kurnool Medical College, Kurnool. A total of 366 post-COVID-19 patients who were suspected and diagnosed probably as post-COVID-19 fungal infections were enrolled during the study period from May 2021 to June 2021. Informed consent was taken from the study population, and all patients were informed regarding the study's usefulness to the community.

### Inclusion Criteria

- All ages of both sexes.
- Post COVID-19 infected patients.
- Suspicious fungal aetiology.

### Exclusion Criteria

- Patients without any history of SARS-CoV2.
- Patients who are on anti-fungal medications.

COVID-19 infections in the general population were detected using microbiological procedures such as RT-PCR, Truenat PCR, and Rapid antigen test of COVID-19. The studied population had undergone endoscopic

procedures to collect tissue bits from nasal cavities at the Department of ENT, Kurnool Medical College, Kurnool. The respective hospital units collected samples such as sputum, BAL, and ET secretions. All various clinical specimens were received at the microbiology department from respective hospital units in sterile normal saline leak-proof containers. These specimens were processed by 10% KOH mount and fungal culture immediately after receiving them at the lab. A microscopy examination was done and observed for fungal hyphal filaments and other fungal elements. Culture samples were inoculated on two sets of Sabouraud dextrose agar and incubated at 25°C and 37°C. Fungal cultures were followed until growth occurred or till 28 days. Positive culture fungal growth was identified by macroscopic and microscopic characteristics. The data was collected into a spread excel sheet and analyzed. Statistical analysis was done using graph pad software. All descriptive variables were presented as numbers or percentages.

## 3. Results

Three hundred sixty-six post-covid patients were enrolled in this study to know the epidemiology and incidence of post-covid mucormycosis. The cumulative incidence rate has been calculated for the study period of May and April months of 2021. The total population at risk at the beginning of the period was 16803, and the number of new cases during the study period was 97; the cumulative incidence was 0.005. 97 (26.5%) patients were diagnosed with fungal infections out of 366 suspected post covid fungal infection cases. Out of 97 post covid fungal infection patients, 33 (34.02%) were female, and 64 (65.9%) were male. The youngest age observed with fungal infection was 32 years, and the eldest age with post covid fungal infection was 71 years. Age and Sex distribution among post covid fungal infection patients showed (Table 1) predominant population was in the age group of 41-60 years; it was 60 out of 97 (61.8%), followed by 61-71 years (24.7%).

**Table 1. Age and sex distribution of Post-COVID-19 fungal infection patients.**

Age in Years	Female	Male	Total	Percentage
31-40	2	11	13	13.4%
41-50	10	21	31	31.9%
51-60	11	18	29	29.8%
61-71	10	14	24	24.7%
Total	33	64	97	100%
Percentage	34.02%	65.9%	100%	-----

Most of the clinical specimens observed were tissue bits from nasal cavities or sinuses; it was 70 out of 97 (72.1%), followed by 13 (13.4%) ET

secretions samples, 8 (8.2%) sputum samples, and 6 (6.1%) nasal swabs (Table 2).

**Table 2. Various samples of post-COVID-19 fungal infections.**

Clinical Specimen	No. of patients	Percentage
Tissue bits from nasal cavities or sinuses	70	72.1%
Sputum	8	8.2%
ET Secretions	13	13.4%

Nasal Swabs	6	6.1%
Total	97	100%

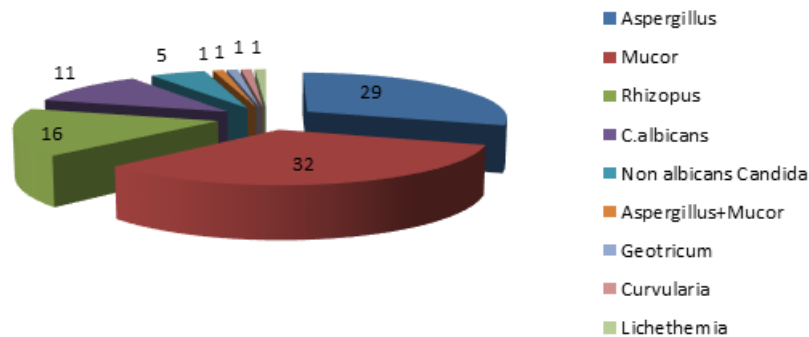
Among 366 total samples, culture-positive and KOH positive was in 25 patients, and culture-positive, and KOH negative were in 6 patients. On the

statistical association between KOH and culture assessment, the p-value was <0.00001, which is considered significant.

**Table 3. KOH and Culture Statistical association in diagnosing fungi.**

Diagnostic Methods		Culture		Total
		Positive	Negative	
KOH	Positive	25	5	30
	Negative	6	330	336
Total		37	350	366

Out of 97 fungal pathogens, Mucor, Aspergillus, and Mucor fungi were isolated predominantly; it was 32 (32.9%), 29 (29.8%), 16 (16.4%), and 11 (11.3%), respectively (Fig1).



**Fig 1. association of COVID-19 with fungal infections.**

#### 4. Discussion

Co-infections and superinfections can be diagnosed in COVID-19 patients as either bacterial/viral/fungal pathogens or a combined pathogenic manifestation. Other than SARS-CoV-2, various pathogens can infect a patient following an initial COVID-19 disease or post-COVID-19 infection.<sup>[6]</sup> While there are rampant SARS-CoV-2 cases in India, the issue of mucormycosis has been emerging as a significant public health problem. The dual infection causes exaggerated human body causes, including dysregulation of the immune system, ciliary dysfunction, cytokine storm, thrombo-inflammation, microvascular coagulation, and eventual immune exhaustion. The two most important clinical presentations of mucormycosis were rhino-orbital mucormycosis and pulmonary mucormycosis. The usual time of presentation of mucormycosis is the third week of onset of COVID-19 symptoms.<sup>[7]</sup> Rhino-orbital mucormycosis involves the paranasal sinuses or orbits and may extend into the cerebral parenchyma.<sup>[8,9]</sup> Risk factors for the increase in mucormycosis in COVID-19 patients include hyperglycemia due to controlled pre-existing diabetes, rampant overuse and irrational use of steroids in the management of COVID-19, new-onset diabetes due to steroid

overuse of severe cases of COVID-19 per se, prolonged ICU stay, irrational use of broad-spectrum antibiotics, pre-existing co-morbidities such as hematological malignancies, use of immunosuppressants, solid organ transplant, etc., breakthrough infections in patients on voriconazole (anti-fungal drug) prophylaxis.<sup>[7]</sup> Mucormycosis clinical manifestations depend on the tissue involved; the usual manifestation is rhino-orbital mucormycosis, which results in common signs and symptoms including one-sided headache, retroorbital pain, nasal stuffiness, nasal discharge, facial or periocular edema or discoloration, epistaxis, and decrease in visual acuity.<sup>[10]</sup>

Post-COVID-19 Mucormycosis has been increasing in India in recent days. Mucormycosis is an aggressive, highly lethal, angioinvasive, opportunistic fungus that invades rhinal, occipital, and cerebral areas. This pathogen can invade craniofacial compartments such as paranasal sinuses, pharynx, orbit, and intracranial cavity via spore spread.<sup>[11]</sup> COVID-19 and mucormycosis are double critical conditions, and it is challenging for physicians to cure those pathogens. It needs aggressive diagnostic modalities to know the extension of fungus in tissues, the exact pathogen responsible for sickness, and any other opportunistic, community, or hospital-acquired

concomitant or superadded infections. Empirical therapy is vital in arresting the spread of Mucorales, especially in immunocompromised or COVID-19 patients. Intense treatment with a multidisciplinary approach may be useful in managing this critical condition. The incidence of fungal infection in SARS patients has been studied in many countries. Zhang Y et al.<sup>[12]</sup> 14.8-27% of fungal infections among SARS-infected patients were reported. Yin CH et al.<sup>[13]</sup> found that the incidence of fungal infection was 21.9-33% in severely ill patients. Li CS et al.<sup>[14]</sup> Fungal infection was a major cause of the increased mortality rate in SARS patients; it was 25-73.7%. Ahmet Dilek et al.<sup>[15]</sup> notified 100 patients of COVID-19-associated mucormycosis from different countries of the world. They stated that out of 100, 68 patients were from India. It shows how mucormycosis encroached on COVID-19 patients in India. In India, still, the incidence of post covid mucormycosis is under-reporting. It might be due to poor diagnostic healthcare infrastructure in rural areas, social stigma among patients, unawareness of clinical manifestations of Mucorales, and less knowledge of the habitat of Mucorales. The higher prevalence of Mucorales in India might be due to many Mucorales in communities and hospitals. Mucormycosis in Southern India was 9. Priya P et al. reported five cases per year during their study period from 2015-2019. Ahmet Dilek et al.<sup>[15]</sup> reported that the most common risk factors behind post covid mucormycosis were overuse of steroids and diabetes mellitus. Mucormycosis is usually present in immunocompromised hosts, but it has also been responsible for infections in immunocompetent hosts.<sup>[16]</sup> In this study, out of 97 post covid fungal infection patients, 33 (34.02%) were female, and 64 (65.9%) were male. The predominant population was in the age group of 41-60 years; there were 60 out of 97 (61.8%), followed by 61-71 years (24.7%). Ahmet Dilek et al.<sup>[15]</sup> found 76% were males. They also found that 90.5% used corticosteroids, 79% had diabetes mellitus, and 34% had hypertension. The higher prevalence of mucormycosis in COVID-19 patients signifies multifactorial involvement; the contributing factors include corticosteroid, diabetes, overuse of antibiotics, overuse of iron or zinc therapies, immunocompromised state, and high environmental temperature. Chakrabarti A et al.<sup>[17]</sup> studied Mucormycosis in India and documented that India has the second-largest diabetic population (65.1 million) worldwide. Mucormycosis incidence was rising in India before the pandemic. The increase in incidence is likely linked to uncontrolled diabetes.<sup>[17]</sup> Karimi-Galougahi M et al.<sup>[18]</sup> reported a COVID-19-associated mucormycosis in an elderly female patient. She had a previous history of usage of remdesivir, interferon-alpha, and systemic corticosteroid. Deepak Garg et al.<sup>[19]</sup> All 8 COVID-19 associated mucormycosis studied cases were affected by Mucorales after 10-14 days of hospitalization. One patient expired out of 8 patients. Out of 97 fungal pathogens, Mucor, Aspergillus, and Mucor fungi were isolated predominantly. It was 32 (32.9%), 29 (29.8%), 16 (16.4%) and 11 (11.3%) respectively. Moorthy A et al.<sup>[20]</sup> A multicentric study in Bangalore, India, was conducted on COVID-19 patients with uncontrolled diabetes. Eighteen patients had fungal infections, including 16 mucormycosis, 1 case of aspergillosis, and 1 mixed fungal infection. Six of these patients expired. Ahmet Dilek et al.<sup>[15]</sup> 33 (33.3%) out of 99 COVID-19-associated mucormycosis patients expired. A retrospective study conducted on COVID-19 critically ill pneumonia patients in Wuhan, China, found that 3 out of 52 (5.8%) patients had fungal infections, including *Aspergillus flavus*, *Aspergillus fumigatus*, and *Candida albicans*.<sup>[21]</sup> A study from Germany on COVID-19-associated invasive pulmonary aspergillosis found that 5 out of 19 (26.3%) had fungal culture positive.<sup>[22]</sup> Chien Ming Chao et al.<sup>[23]</sup> did a systematic review on COVID-19 associated with mucormycosis (CAM) cases by collecting worldwide reports. They observed a higher prevalence in India, Iran, and Egypt than in other countries, especially in the states of Gujarat and

Maharashtra in India. Most severe and critical COVID-19 patients had poor diabetic control and corticosteroid usage as risk factors. Rapid progression of angioinvasive fungus to multiple organs, late manifestations, and shortage of anti-fungal drugs during the COVID-19 pandemic has been a burden in treating the patients. These global pandemic times need current and effective anti-fungal drugs and other management approaches for the needy population.<sup>[24]</sup>

## 5. Conclusion

We conclude that Mucor, Rhizopus, and Aspergillus species were predominantly noted in COVID-19-associated fungal infections. Males were most affected, and the majority were in the age group of 41-60 years. Most of the samples processed were nasal tissue bits, indicating that mucormycosis is more toward rhino-orbital mucormycosis. Early diagnosis and treatment will help to manage SARS-CoV-2-associated fungal infections. Rhinorbital mucormycosis is a rapidly progressive condition, so empirical management with a KOH stain report may benefit the patient before the culture report arrives. The formulation of stringent infection control protocols, antimicrobial usage policy, and updated COVID-19 management guidelines by government authorities helps reduce infections.

## Conflict of Interest

The authors declared that there is no conflict of interest.

## Acknowledgements

This research received no specific grant from any funding agency in the public, commercial, or not-for-profit sectors.

## References

- [1] American Thoracic Society, Centers for Disease Control and Prevention, Infectious Diseases Society of America. American thoracic society/centers for disease control and prevention/infectious diseases society of america: controlling tuberculosis in the United States. *American journal of respiratory and critical care medicine*. 2005;172(9):1169-227. <https://doi.org/10.1164/rccm.2508001>.
- [2] Cohen J. Wuhan seafood market may not be source of novel virus spreading globally. *Science*. 2020;10(10.1126).
- [3] Chen J. COVID-19 Scientific Advisory Group Rapid Response Report. Alberta Health Services. 2020.
- [4] WHO Director-General's opening remarks at the media briefing on COVID-19 - 11 March 2020. World Health Organization (WHO). 2020.
- [5] Ferguson BJ. Mucormycosis of the nose and paranasal sinuses. *Otolaryngologic Clinics of North America*. 2000;33(2):349-65. [https://doi.org/10.1016/S0030-6665\(00\)80010-9](https://doi.org/10.1016/S0030-6665(00)80010-9).
- [6] Bengoechea JA, Bamford CG. SAR-CoV-2, bacterial co-infections, and AMR: the deadly trio in COVID-19?. *EMBO molecular medicine*. 2020;12(7):e12560. <https://doi.org/10.15252/emmm.202012560>.
- [7] Kumari A, Rao NP, Patnaik U, Malik V, Tevatia MS, Thakur S, et al. Management outcomes of mucormycosis in COVID-19 patients: A preliminary report from a tertiary care hospital. *medical journal armed forces india*. 2021;77(2):S289-95. <https://doi.org/10.1016/j.mjafi.2021.06.009>.
- [8] Ferguson BJ. Mucormycosis of the nose and paranasal sinuses. *Otolaryngologic Clinics of North America*. 2000;33(2):349-65. [https://doi.org/10.1016/S0030-6665\(00\)80010-9](https://doi.org/10.1016/S0030-6665(00)80010-9).
- [9] Werthman-Ehrenreich A. Mucormycosis with orbital compartment syndrome in a patient with COVID-19. *The American journal of*

- emergency medicine. 2021;42:264-e5. <https://doi.org/10.1016/j.ajem.2020.09.032>.
- [10] Honavar SG. Code mucor: guidelines for the diagnosis, staging and management of rhino-orbito-cerebral mucormycosis in the setting of COVID-19. *Indian journal of ophthalmology*. 2021;69(6):1361-65. [https://doi.org/10.4103/ijoo.IJO\\_1165\\_21](https://doi.org/10.4103/ijoo.IJO_1165_21).
- [11] Ravani SA, Agrawal GA, Leuva PA, Modi PH, Amin KD. Rise of the phoenix: Mucormycosis in COVID-19 times. *Indian journal of ophthalmology*. 2021;69(6):1563-68. [https://doi.org/10.4103/ijoo.IJO\\_310\\_21](https://doi.org/10.4103/ijoo.IJO_310_21).
- [12] Zhang Y, Li WX, Huang KW, Cao ZX, Hao JY. Hospital acquired pneumonia occurring after acute stage of the serious SARS and its treating strategies. *Chin J Nosocomiol*. 2003;11(13):1081-7.
- [13] Yin CH, Wang C, Tang Z. Clinical analysis of 197 patients with critical severe acute respiratory syndrome in Beijing areas. *CHINESE JOURNAL OF CRITICAL CARE MEDICINE*. 2004;24(4):248-9.
- [14] Li CS, Pan SF. Analysis and causation discussion of 185 severe acute respiratory syndrome dead cases. *Zhongguo wei zhong bing ji jiu yi xue= Chinese critical care medicine= Zhongguo weizhongbing jijiuyixue*. 2003;15(10):582-4.
- [15] Dilek A, Ozaras R, Ozkaya S, Sunbul M, Sen EI, Leblebicioglu H. COVID-19-associated mucormycosis: case report and systematic review. *Travel medicine and infectious disease*. 2021;44:102148. <https://doi.org/10.1016/j.tmaid.2021.102148>.
- [16] Patel A, Kaur H, Xess I, Michael JS, Savio J, Rudramurthy S, et al. A multicentre observational study on the epidemiology, risk factors, management and outcomes of mucormycosis in India. *Clinical microbiology and infection*. 2020;26(7):944-e9. <https://doi.org/10.1016/j.cmi.2019.11.021>.
- [17] Chakrabarti A, Singh R. Mucormycosis in India: unique features. *Mycoses*. 2014;57:85-90.
- [18] Karimi-Galougahi M, Arastou S, Haseli S. Fulminant mucormycosis complicating coronavirus disease 2019 (COVID-19). In *International forum of allergy & rhinology* 2021;11(6):1029-30. <https://doi.org/10.1002/alar.22785>.
- [19] Garg D, Muthu V, Sehgal IS, Ramachandran R, Kaur H, Bhalla A, et al. Coronavirus disease (Covid-19) associated mucormycosis (CAM): case report and systematic review of literature. *Mycopathologia*. 2021;186(2):289-98. <https://doi.org/10.1007/s11046-021-00528-2>.
- [20] Moorthy A, Gaikwad R, Krishna S, Hegde R, Tripathi KK, Kale PG, et al. SARS-CoV-2, uncontrolled diabetes and corticosteroids—an unholy trinity in invasive fungal infections of the maxillofacial region? A retrospective, multi-centric analysis. *Journal of maxillofacial and oral surgery*. 2021;20(3):418-25. <https://doi.org/10.1007/s12663-021-01532-1>.
- [21] Yang X, Yu Y, Xu J, Shu H, Liu H, Wu Y, et al. Clinical course and outcomes of critically ill patients with SARS-CoV-2 pneumonia in Wuhan, China: a single-centered, retrospective, observational study. *The Lancet Respiratory Medicine*. 2020;8(5):475-81. [https://doi.org/10.1016/S2213-2600\(20\)30079-5](https://doi.org/10.1016/S2213-2600(20)30079-5).
- [22] Koehler P, Cornely OA, Böttiger BW, Dusse F, Eichenauer DA, Fuchs F, et al. COVID-19 associated pulmonary aspergillosis. *Mycoses*. 2020;63(6):528-34. <https://doi.org/10.1111/myc.13096>.
- [23] Chao CM, Lai CC, Yu WL. COVID-19 associated mucormycosis—An emerging threat. *Journal of Microbiology, Immunology and Infection*. 2022;55(2):183-90. <https://doi.org/10.1016/j.jmii.2021.12.007>.
- [24] Dogra S, Aggarwal A, Passi G, Sharma A, Singh G, Barnwal RP. Mucormycosis amid COVID-19 crisis: pathogenesis, diagnosis and novel treatment strategies to combat the spread. *Frontiers in microbiology*. 2022;12:1-27. <https://doi.org/10.3389/fmicb.2021.794176>.

**How to Cite this Article:** Munipati S, Rachamadugu H, Avileli S, Avula R, Beladona NJ, Boyapally SR. Microbiological Profile of Post-COVID-19 Mucormycosis in Various Samples. *International Journal of Scientific Research in Dental and Medical Sciences*. 2022;4(2):87-91. <http://doi.org/10.30485/IJSRDMS.2022.338567.1285>.