



Histologic Evaluation of New Doxycycline Gel Formulation for Subgingival Application in Experimental Periodontitis in Rats

Ali Mohammad Tamaddon^a, Faezeh Saadati^{b,*}, Hengameh Khosropanah^b, Ali Deghani Nazhvani^c, Gholam Hossein Yousefi^a

^a Center for Nanotechnology in Drug Delivery, School of Pharmacy, Shiraz University of Medical Sciences, Shiraz, Fars, Iran

^b Department of Periodontics, School of Dentistry, Shiraz University of Medical Sciences, Shiraz, Iran

^c Department of Oral and Maxillofacial Pathology, School of Dentistry, Shiraz University of Medical Sciences, Shiraz, Fars, Iran

ARTICLE INFO

Article history:

Received 07 September 2020

Received in revised form 18 October 2020

Accepted 18 November 2020

Available online 23 November 2020

Keywords:

Doxycycline
Histology
Periodontitis

ABSTRACT

Background and aim: Adjunctive therapy can increase periodontal treatments' success, and to date, various drugs had been suggested. This study aimed to test the efficacy of a new formulation of locally delivered- slow-releasing 10% doxycycline (DOX) gel as a thermogelating system by histologic evaluation in rats with experimental periodontitis.

Materials and methods: Periodontal disease was induced with a ligature in maxillary left and right upper first molars of twenty male Sprague-Dawley rats in a seven-day duration. Left molars were treated with DOX gel while the right ones received vehicle drug in the subgingival area. Animals were randomly divided into two groups (each group contained ten rats). One group received the drug only once, while the second one was treated with twice the drug's application. After seven days, animals were killed and prepared for histologic evaluation.

Results: Application of DOX gel reduced the degree of inflammation, presence of osteoclasts and resorptive lacuna, and the amount of disorientated collagen fibres after one week compared to teeth treated with vehicle drug ($p < 0.05$) after twice application of the drug no adverse effect and necrotic changes were detected in histologic evaluations.

Conclusion: This novel formulation of DOX gel is an effective and safe drug for treating periodontal disease in rats. It seems that the drug can be tested in human clinical trials as an adjunctive treatment for periodontal disease.

1. Introduction

Periodontal disease can be defined as an inherited or acquired disorder of periodontium. It has been proved that the primary etiologic factor of periodontal disease is microbial plaque.^[1, 2] Mouth microflora contains hundreds of aerobic and anaerobic bacteria species such as *Aggregatibacter actinomycetemcomitans*, *Porphyromonas gingivalis* and *Tannerella forsythia*. Those organisms can grow as complex and mixed colonies in biofilm on tooth surfaces.^[3] Supragingival bacterial counts can exceed 1×10^9 bacteria. Subgingival bacterial counts range from 1×10^3 in a healthy shallow crevice to more than 1×10^8 in a periodontal pocket.^[4] Periodontal treatment is based on anti-infective non-surgical treatment to manage the biofilm and other prominent risk factors. Combined with improved personal oral hygiene, this non-surgical therapy will reduce inflammation of the tissue and Pocket Probing Depth (PPD). Clinical periodontal attachment gain can also be a result of non-surgical therapy.^[5-8] The term mechanical therapy refers to Scaling and

Root Planning (SRP), both supragingival and subgingival, which means debridement of the tooth surface by the meticulous use of hand or power-driven scalers. This debridement aims to remove plaque, endotoxin, calculus, and other plaque-retentive local factors.^[9] The antibacterial effect of SRP is generally caused either by a reduction in bacterial load or a change in the composition of the bacterial flora at the periodontal site. The effect of mechanical treatment alone on antibacterial is incomplete because of inaccessible areas of the root surface. Thus there is a good rationale to augment the antibacterial effect of mechanical therapy chemically.^[10]

Since periodontal disease and also periodontal treatment are associated with bacteria, the antimicrobial treatment seems appropriate.^[11] However, due to the concern about the development of bacterial resistance induced over long periods, the systemic route of antibiotic administration may not be ideal. Over a long period, systemic antibiotic therapy also increases the risk of

* Corresponding author. Faezeh Saadati

E-mail address: faezeh2011@gmail.com

Department of Periodontics, School of Dentistry, Shiraz University of Medical Sciences, Shiraz, Iran

<http://doi.org/10.30485/IJSRDMS.2020.247105.1084>



undesirable side effects like nausea, diarrhea, fever, abdominal pain, and pseudomembranous colitis.^[12, 13] The local delivery of antimicrobial therapy to periodontal pockets has the benefit of putting more drugs at the target site and minimizing exposure of the total body to the drug.^[14] Various methods to deliver antimicrobial agents into periodontal pockets have been advised and subjected to numerous study types. The drugs investigated for local application include tetracycline, minocycline, doxycycline, metronidazole, azithromycin, and chlorhexidine. The agents were administered using the following devices: varnishes (chlorhexidine), gels (doxycycline, metronidazole, minocycline, azithromycin), non-resorbable polymer fibres (tetracycline), gelatin chips (chlorhexidine), ointments (tetracycline), and resorbable polymer microspheres (minocycline).^[15]

2. Materials and methods

Doxycycline Hyclate

Doxycycline (Dox), a semi-synthetic derivative of oxytetracycline, is a cheap and potent antibacterial drug commonly used as the Doxycycline Hyclate (DOX-h). It differs from oxytetracycline, chlortetracycline, and tetracycline in that it is 5-10 times more lipophilic.^[16] Therefore, it has higher tissue penetration, greater distribution volume, and better antimicrobial properties, given that entry into bacteria is not based on an active transportation mechanism as it occurs with the tetracyclines referred to above. Dox also has a longer half-life and a higher binding rate of plasma proteins in humans and animals.^[17, 18]

DOX-h's Broad Spectrum-antimicrobial effects are focused on hindering bacterial protein synthesis, interfering with the binding of aminoacyl-tRNA to the mRNA ribosome's complex, thus arresting growth.^[19] This action mechanism has been linked to optimum clinical outcomes when the drug is administered to a time-dependent effect.^[20] which means that, ideally, serum DOX concentrations should never be below MIC at any time during the dosing period.^[21]

Doxycycline Hyclate in a Biodegradable Polymer

A two-syringe mixing system for the controlled release of doxycycline (Atridox; Block Drug, Jersey City, NJ, USA) has been available commercially for some years. One syringe contains the delivery vehicle, flowable bioabsorbable poly (DL-Lactide) dissolved in N-methyl-2-pyrrolidone, and the other a doxycycline hyclate powder.^[15] The DOX gel is indicated for treating chronic adult periodontitis for a gain in clinical attachment level (CAL), reduction in PPD, and reduction of Bleeding On probing (BOP). The gel has been reported to release DOX within the GCF over seven days. The DOX gel is biodegradable and does not require removal. After mixing the contents of two syringes, if not immediately used, the mixed contents can be kept in an airtight container at room temperature for three days. The DOX gel is used by directly injecting the mixed contents of the two syringes into the pocket through the cannula connected to the syringe until the pocket is filled in completely. The pockets' contents are then covered with either a periodontal dressing or a dental adhesive of cyanoacrylate.^[10] We evaluated an alternative local delivery drug, which is less expensive, more available, less technique sensitive, and more practical. We designed a less expensive, thermosensitive gel-forming system based on poloxamer 127 and methylcellulose. We evaluated the histologic effect of subgingival application of this novel formulation in experimental periodontitis in rats.

Poloxamer aqueous solutions show thermoreversible properties, which present great interest in optimizing drug formulation. The phenomenon of thermogelling is entirely reversible and is characterized by a sol-gel transition

temperature, and it has some medical uses, such as vaginal application.^[22, 23] Methylcellulose also has the property of forming gels on heating and reverting to solution-state on cooling. Poloxamer solution itself forms a gel at high temperature. In this study, methylcellulose is added to the formulation to improve the gel's rheological characteristics, and the mixture of poloxamer and methylcellulose introduces a mixture with temperature-dependent behavior.^[24]

The amount of poloxamer, methylcellulose, and DOX can determine the temperature at which the fluid form drug changes into the gel form. The optimal amount of them is also necessary for proper syringibility. We found the best formulation with good handling properties, and then we tested this novel formulation as adjunctive therapy for the treatment of periodontal disease by histological evaluations. Based on our searches, this was the first time a thermoregulating system of the locally delivered drug was designed and prepared for periodontal treatments.

Preparation of In-situ Polymer Gel

A solution of 15 % w/w poloxamer was prepared in ice-cooled normal saline. Then, methylcellulose at the final concentration of 0.5% w/w was added to the poloxamer solution while mixing smoothly. When a homogenous transparent solution was obtained, 10 % w/w of Dox was added. Determine gel formation at 37°C; the tube inversion method was used. The product was put in a test tube. The temperature was raised to 37°C, and the polymer state's transition from sol (with the flow) to gel (no flow) was determined. The resultant suspension was filled into 1 ml insulin syringes and stored at 4 °C. This formulation showed proper organoleptic properties. The resultant composition was liquid and syringeable at room temperature, but when the temperature increased to 37 °C, it formed a thermo-reversible gel.

Drug Release

The drug release was determined by an in-house release method (Figure. 1). Dox gel (1 ml) was poured into a dialysis tube (6-8 kD, Float-A-Lyzer G2, Spectrum), which is inserted into a vessel containing 9 ml of saliva simulating medium (potassium chloride 0.72g/L, sodium chloride 0.6 g/L, Citric acid 0.03 g/L, di-sodium hydrogen phosphate 0.866 g/L, potassium di-hydrogen phosphate 0.68 g/L, potassium bicarbonate 1.5 g/L) at 37 °C.

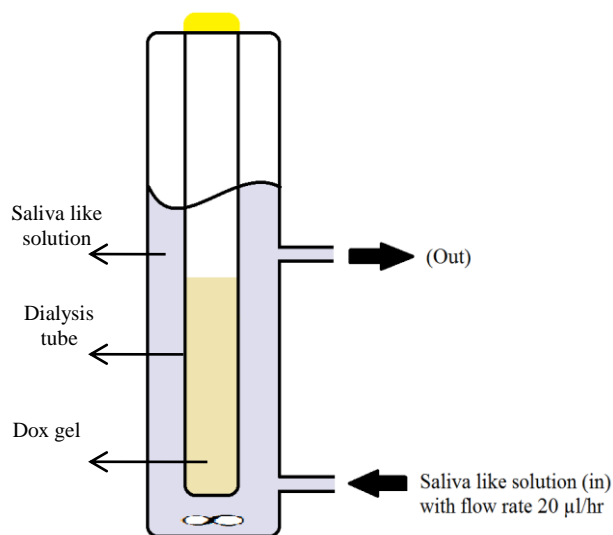


Fig. 1. Determination of the drug release by an in-house release method.

The medium was pumped into the vessel at a constant flow rate of 20 μ l/hr, similar to the crevicular fluid. Samples were collected at different time intervals (2, 4, 6, 24, 48, 72, 96 & 120 hrs). The amount of released Dox was measured using UV-visible spectroscopy at 237 nm from the calibration curve plotted at various Dox concentrations in water with pH=3.5. The drug release from the gel (more than 90%) was sustained over five days. (Fig. 2).

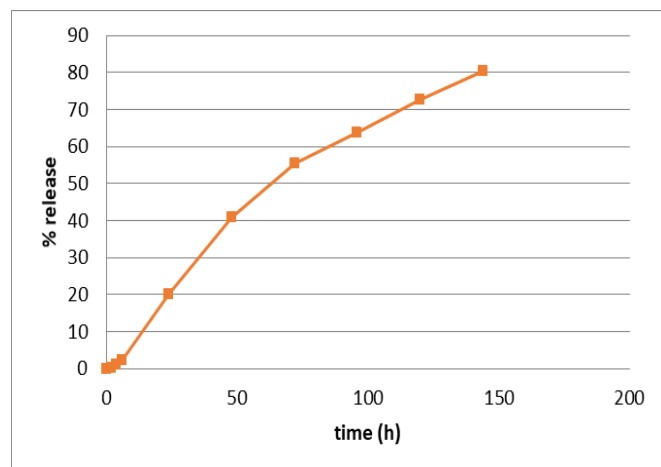


Fig. 2. releasing pattern of the doxycycline gel.

Animals

This experimental animal study was carried out by the U.K. Animals (Scientific Procedures) Act, 1986 and associated guidelines, E.U. Directive 2010/63/E.U. for animal experiments. Twenty male Sprague Dawley rats (similar age; weight: 220-250 g) were housed in a controlled room temperature and received water and food ad libitum. All experiments were conducted following local guidelines of the animal laboratory center of Shiraz University of Medical Sciences with the university ethic approval number: I.R.SUMS.REC.1394.S819.

Induction of Experimental Periodontitis

A sterile silk (000) thread ligature (SUPA MEDICAL DEVICES) was placed around the cervix of the first right and left upper molars of all rats, which were anesthetized with ketamine 10% (alfasan; WOERDEN-HOLLAND), (0.4 ml/kg) and xylazine 2% (alfasan; WOERDEN-HOLLAND), (0.2 ml/kg) via intramuscular injection. The ligatures were knotted on the buccal side of the teeth. During the procedure, all rats received a soft ground diet to facilitate plaque accumulation.

Subgingival Application of the Drug

Maxillary left first molars were randomly selected as a test group for application of test gel which contained DOX (DOX group), and maxillary right first molars were allocated as the control group which received vehicle gel (vehicle group). Animals were divided into two groups (each group contained ten rats): the first group received DOX and vehicle gels only once (one week after induction of periodontitis). The second group received two times subgingival application of DOX and vehicle gels with a one-week interval. Periodontitis was induced, and ligatures were removed after one week. The DOX gel was applied in the gingival sulcus of the left maxillary first molar teeth of all rats, and the right sides received vehicle gel, and drug application was made until the pocket was filled. This process was done for all rats (first and second groups).

Seven days later, animals of the first group were euthanized based on animal ethics consensus with the administration of a lethal dose of inhaled ether. Their maxillary bones were dissected, washed with N.S., and put in the bottle containing 10% formalin. The samples were sent for histological evaluations. The same drug application procedure was done for the second group, and the rats were euthanized after the second week.

Histologic Evaluation

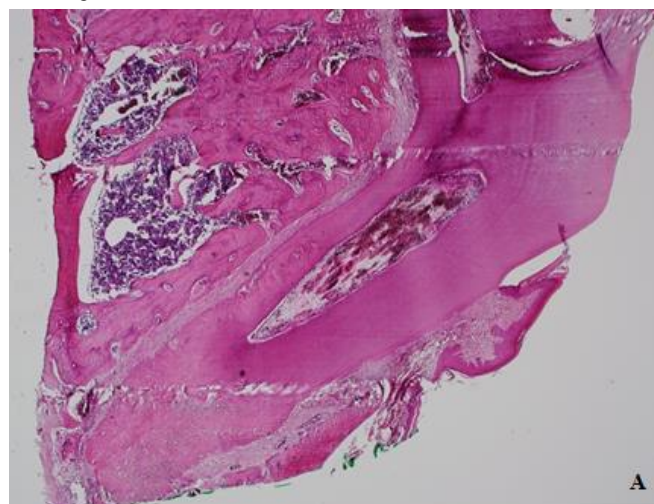
Both left and right upper first molars were sectioned, trimmed, and fixed in 4% paraformaldehyde. The samples were decalcified by 10% nitric acid in 48 hours. Then they were placed in paraffin blocks. Serial mesiodistal sections (5 μ m thick) were cut from the cervical to the apical area. Sections were designed to show mesial and distal alveolar crestal bone of first molars and furcation area. The sections were placed on glass slides, de-paraffinized, and hydrated. Finally, staining of Hematoxyline-Eosin (H&E) was performed. An experienced oral pathologist viewed all the slides in a single-blind manner with a light microscope (Olympus-BX42, UK). Sections were viewed to discover the grade of inflammatory cell infiltration, alveolar bone resorption, and changes in collagen fibers' orientation in the periodontium. The infiltration of inflammatory cells in periodontium was graded as negative (0), mild (1), moderate (2), and severe (3). The presence of osteoclasts and resorptive lacunas indicates alveolar bone resorption, shown by (0) as absent and (1) present. Also, organized collagen fibres took (1) and nonorganized collagen fibres assigned as (0).^[25]

Statistical Analysis

Kruskal-Wallis H and Dunn tests were used to compare the amount of inflammation, bone resorption, and functional collagen fibers between different groups. SPSS version 22.0 (IBM SPSS) was used for data analysis. P<0.05 was considered statistically significant.

3. Results

The study was conducted on 20 rats, divided into two groups. The first group's animals received to test and control drugs only once, but the second group was treated with twice the drugs' application. In the second application, one rat was dead due to receiving a higher dose of an anesthetizing drug. The Histologic evaluation was done to determine the severity of inflammation, loss of orientation of collagen fibers, and osteoclast and resorptive lacuna in different tooth surfaces (mesial, furcation area, and the distal surface of the root) (Figs. 3-4).



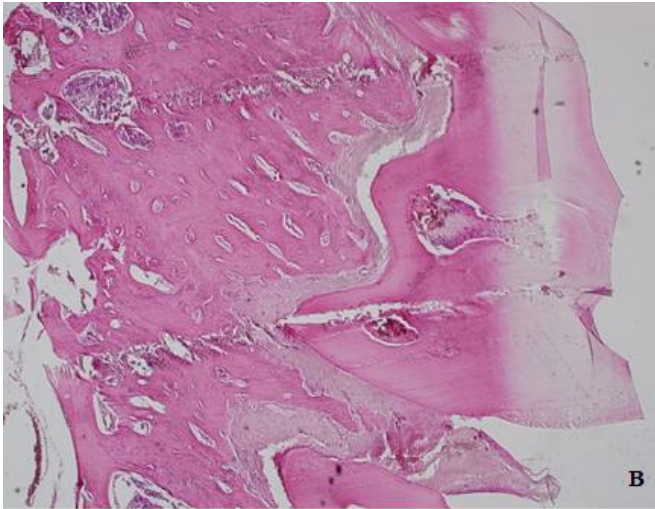


Fig. 3. Mesial root, alveolar process & furcation (A), Distal root, alveolar process & furcation (B) of first rat molar and its periodontium. Note the organized collagen fibers with no inflammation and no bone resorption (H&E staining, 100X).

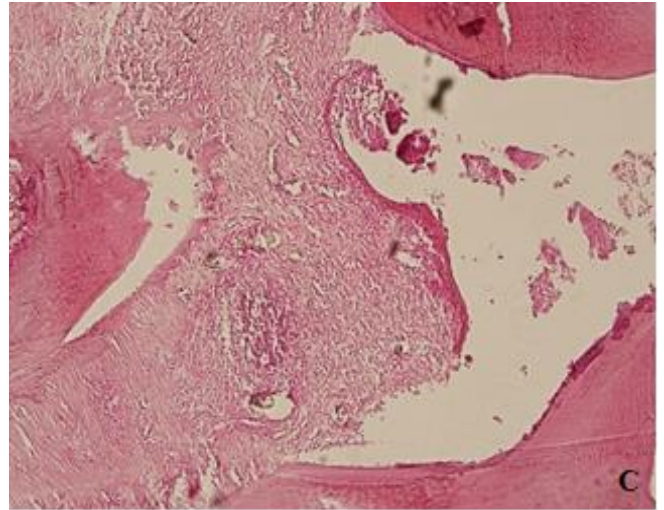
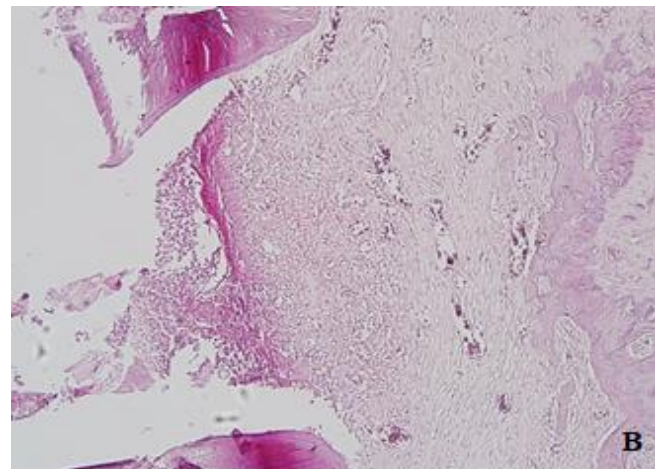
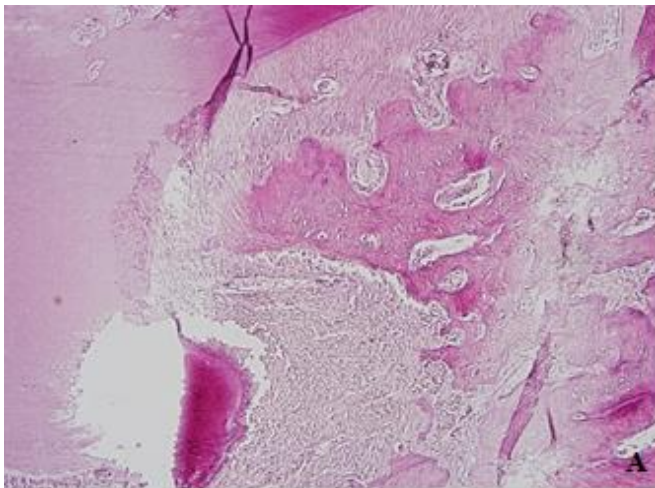


Fig. 4. Mild inflammation, bone resorption & loss of collagen fiber orientation in the furcation area (A), Moderate inflammation, bone resorption & loss of orientation in the distal area (B), Severe inflammation with follicle formation, bone resorption & loss of orientation in the distal area (C) of the diseased periodontium (H&E staining, 200X).



A comparison was made between the rats' test and control teeth, which only once received the drug (DOX group 1 and vehicle group 1). The same comparison was also made for test and control teeth of the rats treated with two times the application of the drug (DOX group 2 and vehicle group 2). The number of areas that present bone resorption and functionally orientated collagen fibers were used in the statistical analysis. When we compared the mean inflammation in all test and control teeth surfaces, a significant result was achieved for DOX group 1 and vehicle group 1 ($p = 0.014$), with less inflammation in the DOX group. This comparison was not significant in the second group ($p = 0.058$). When comparing four groups together, the vehicle group1 had the most severe inflammation (Chart 1).

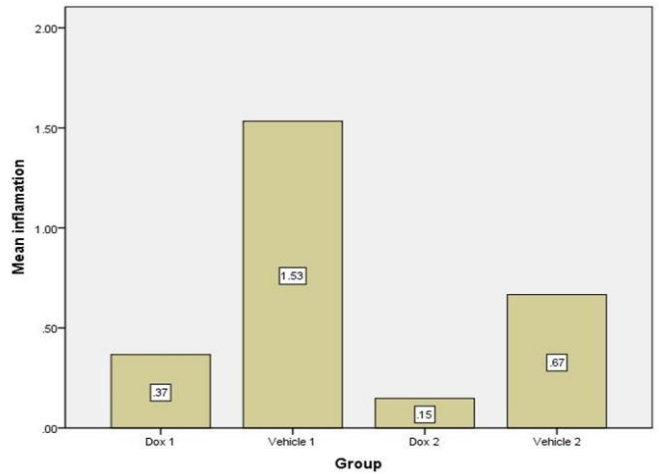


Chart 1. comparing the amount of inflammation, DOX 1: teeth treated with doxycycline gel only once, Vehicle 1: teeth treated with vehicle gel only once, DOX 2: teeth treated with doxycycline gel twice, Vehicle 2: teeth treated with vehicle gel twice.

Another variable compared between the groups was osteoclasts, and resorptive lacuna addressed as bone resorption in this paper. The bone resorption status was different between DOX group 1 and vehicle group 1 ($p = 0.03$), with more bone resorption in the vehicle group. Still, the difference

was not significant when comparing DOX group 2 and vehicle group 2 ($p = 0.148$). The bone resorption was more in-vehicle group 1 when comparing all the four groups (Chart 2).

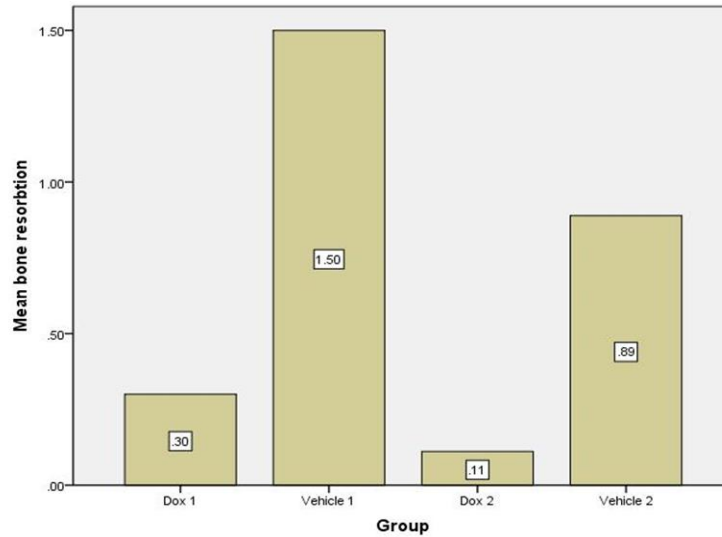


Chart 2. comparing the amount of bone resorption.

In histologic evaluation, we also focused on the orientation of collagen fibers and analyzed the results. Disorientation of collagen fibers was more in-vehicle groups. This variable was significant between DOX group 1 and

vehicle group 1 ($p = 0.010$) but not meaningful between DOX group 2 and vehicle group 2 ($p = 1.000$). Vehicle group 1 had the least amount of functionally oriented collagen fibers (Chart 3).

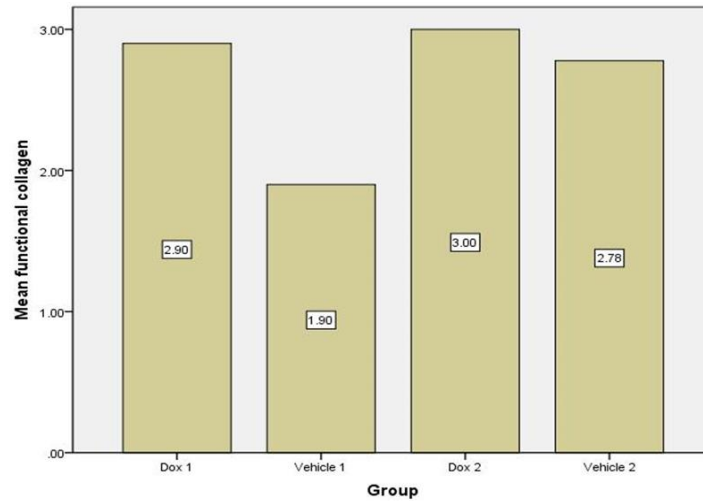


Chart 3. comparing the amount of collagen fibers with functional Orientation.

Table 1. The general characteristics of the groups.

Group	Ave_inflammation	Inflammation	Resorption	Oriented collagen fibers
Dox 1 N	10	10	10	10
Mean	0.3667	1.1000	0.3000	2.9000
Std.Deviation	0.18922	0.56765	0.48305	0.31623
Median	0.3333	1.0000	0.0000	3.0000
Minimum	0.00	0.00	0.00	2.00

Maximum	0.67	2.00	1.00	3.00
vehicle1 N	10	10	10	10
Mean	1.5333	4.600	1.5000	1.9000
Std.Deviation	1.41596	4.24788	0.52705	0.99443
Median	1.1667	3.5000	1.5000	2.0000
Minimum	0.33	1.00	1.00	0.00
Maximum	9.00	3.00	2.00	3.00
P-value	----	0.014	0.03	0.010
Dox 2 N	9.00	9.00	9.00	9.00
Mean	0.1481	0.4444	0.1111	3.0000
Std.Deviation	0.17568	0.52705	0.33333	0.0000
Median	0.0000	0.0000	0.0000	3.0000
Minimum	0.00	0.00	0.00	3.00
Maximum	0.33	1.00	1.00	3.00
Vehicle2 N	9.00	9.00	9.00	9.00
Mean	0.6667	2.0000	0.8889	2.7778
Std.Deviation	0.44096	1.32288	0.78174	0.44096
Median	0.6667	2.0000	1.0000	3.0000
Minimum	0.00	0.00	0.00	2.00
Maximum	1.33	4.00	2.00	3.00
P-value	----	0.058	0.148	1.000

Ave inflammation: average inflammation, DOX 1: teeth treated with doxycycline gel only once
 Vehicle 1: teeth treated with vehicle gel only once, DOX 2: teeth treated with doxycycline gel twice
 Vehicle 2: teeth treated with vehicle gel twice.

4. Discussion

Periodontal treatment aims to reduce the amount of bacterial accumulation as much as possible, but the antibacterial effect of mechanical treatment alone is incomplete; therefore, mechanical therapy's antibacterial effect is well rationalized to increase chemically.^[10] Gupta et al. compared the efficacy of subgingivally delivered 10 % doxycycline hyclate and xanthan-based chlorhexidine (CHX) gels when used as an adjunct to SRP in the treatment of chronic periodontitis. At three months, differences in relative CAL between SRP+DOX (0.80 ± 0.92) and SRP+CHX (0.63 ± 1.47) and SRP alone were statistically significant.^[26] Another study demonstrated that DOX's subgingival application could induce a clinically significant CAL gain (2 mm).^[27] Studies have shown that local doxycycline can be an important adjunct in smokers for active and supportive treatments of severe periodontal disease.^[28]

The efficacy of locally delivered DOX during supportive periodontal therapy has also been proved.^[29] The anti-inflammatory effect of subgingivally delivered nanostructured DOX gel was evaluated in a clinical study. The results suggest that treatment with this nanostructured gel can improve clinical parameters and inflammatory markers in patients with periodontal disease.^[30] The present study tried to design a thermo-sensitive gel-forming system based on poloxamer F-127 and methylcellulose. This gel is liquid at room temperature and becomes semi-solid in temperatures higher than 350 °C. This experimental study was conducted on rats to evaluate the drug toxicity and biocompatibility, and the effect of the drug on periodontal disease histological parameters such as inflammation, collagen fibers orientation, and bone resorption. However, periodontitis induced in laboratory animals has not the complexities of Chronic periodontitis in humans but is considered a useful method to evaluate therapeutic agents.

The induction of periodontal disease by placing ligatures around the cervical portion of the teeth has been used in many different animals. Still, the rat ligature model has been of considerable interest recently. 6500 The ligature increases dental plaque accumulation and induces micro-ulceration in the sulcular epithelium. This damage facilitates periopathogens' invasion into the underlying connective tissue. Several studies have shown that periodontal attachment loss and alveolar bone resorption in rats occurs predictably within seven days.^[31-35] In this study, ligatures, irritable factors were removed after the induction of periodontitis. Ligature removal has the same role as phase 1 of periodontal treatments, named as a cause-related phase. After eliminating causal factors, adjunctive therapy is needed to facilitate periodontal healing. The Emphasizes the adjunctive and complementary role of locally delivered drugs. Our DOX locally delivered drug's releasing pattern showed that more than 90% of the drug was released after five days, so the first group of rats was killed after one week when the drug's release was almost completed. To evaluate the novel drug's adverse effects and compare it to that of vehicle drug, we repeated drug application after seven days. We waited one more week to obtain more histologic information. Increased numbers of drug applications can increase some adverse effects.^[36] after twice applying the drug, based on Histologic analyses and tissue response, the drug's biocompatibility can be checked. None of the samples showed any degenerative or necrotic changes, which can be interpreted as drug biocompatibility. In the present study, the difference in the degree of inflammation was significant between DOX group 1 and vehicle group 1 ($p = 0.014$). Same results were obtained for bone resorption and disorientation of collagen fibers. The amount of bone resorption was different between DOX group 1 and vehicle group 1 ($p = 0.03$), with more bone resorption in the vehicle group. The severity of bone resorption was more in-vehicle group 1 when comparing all the four groups. Disorientation of collagen fibers was more severe in vehicle groups. The difference was significant between DOX group 1 and vehicle group 1 ($p = 0.010$). When comparing all four groups, the disorientation of collagen fibers was the most of all seen in vehicle group 1.

When considering inflammation, bone resorption, and collagen fibers' orientation, there was no difference between DOX group 2 and vehicle group 2. No degenerative or necrotic changes were detected after twice the application of the drug. One histologic study evaluated the topical application of doxycycline in reimplanted monkey incisors on pulp revascularization and periodontal healing. The results showed that doxycycline could decrease the ankylosis and inflammatory root resorption levels compared with the teeth control group. Authors claimed that doxycycline during the extra-alveolar time was most probably exerted on the micro-organisms that contaminated the root surface.^[25] This study follows our study, in which DOX decreased inflammation and bone resorption and improved periodontal healing. These events were probably the impact of DOX's antimicrobial effect on bacterial plaque accumulation after ligature placement.

5. Conclusion

The Histologic evaluation of this study showed that subgingival administration of this new formulation of DOX in rats with experimental periodontitis could reduce the severity of inflammation, disoriented collagen fibers, and also the presence of osteoclast and resorptive lacuna in the bone. Histological evaluations confirmed this drug's safety on surrounding structures during limited administration since no necrotic or degenerative changes were observed even after twice the application of the drug. Further in vitro and in vivo studies to evaluate drug toxicity, substantivity, and frequency of its usage are suggested. Also, clinical and histological

comparison of this antimicrobial agent with the other commercial products is necessary.

Conflict of Interest

The authors declared that there is no conflict of interest.

Acknowledgments

The authors thank the Vice-Chancellery of Shiraz University of Medical Sciences for supporting this research (Grant#94-01-03-9893). This manuscript is based on the thesis by Dr. Faezeh Saadati. The authors also thank Dr. Mohammad Vosugh of the Center for Research Improvement of the School of Dentistry for the Statistical analysis.

References

- [1] Armitage GC. Periodontal diagnoses and classification of periodontal diseases. *Periodontology* 2000. 2004;34(1):9-21.
- [2] Jordan RC. Diagnosis of periodontal manifestations of systemic diseases. *Periodontology* 2000. 2004;34(1):217-29. <https://doi.org/10.1046/j.0906-6713.2002.003433.x>.
- [3] Listgarten MA. Structure of the microbial flora associated with periodontal health and disease in man: a light and electron microscopic study. *Journal of periodontology*. 1976;47(1):1-8. <https://doi.org/10.1902/jop.1976.47.1.1>.
- [4] Socransky SS. Microbiology of periodontal disease—present status and future considerations. *Journal of periodontology*. 1977;48(9):497-504. <https://doi.org/10.1902/jop.1977.48.9.497>.
- [5] Cobb CM. Clinical significance of non - surgical periodontal therapy: an evidence - based perspective of scaling and root planing. *Journal of Clinical Periodontology*. 2002;29:22-32. <https://doi.org/10.1034/j.1600-051X.29.s2.4.x>.
- [6] Cobb CM. Non - surgical pocket therapy: Mechanical. *Annals of periodontology*. 1996;1(1):443-90. <https://doi.org/10.1902/annals.1996.1.1.443>.
- [7] Suvan JE. Effectiveness of mechanical nonsurgical pocket therapy. *Periodontology* 2000. 2005;37(1):48-71. <https://doi.org/10.1111/j.1600-0757.2004.03794.x>.
- [8] Drisko CH. Nonsurgical periodontal therapy. *Periodontology*. 2001;25:77-88.
- [9] Twetman S. Oral biofilms in health and disease. *Annals of the Royal Australasian College of Dental Surgeons*. 2016;23:26.
- [10] Newman MG, Takei H, Klokkevold PR, Carranza FA. Carranza's clinical periodontology. Elsevier health sciences; 2011.
- [11] Pretzl B, Sälzer S, Ehmke B, Schlagenhauf U, Dannewitz B, Dommisch H, Eickholz P, Jockel-Schneider Y. Administration of systemic antibiotics during non-surgical periodontal therapy—A consensus report. *Clinical oral investigations*. 2019;23(7):3073-85. <https://doi.org/10.1007/s00784-018-2727-0>.
- [12] Southard GL, Godowski KC. Subgingival controlled release of antimicrobial agents in the treatment of periodontal disease. *International journal of antimicrobial agents*. 1998;9(4):239-53. [https://doi.org/10.1016/S0924-8579\(98\)00004-1](https://doi.org/10.1016/S0924-8579(98)00004-1).
- [13] Aggarwal G, Verma S, Gupta M, Nagpal M. Local Drug Delivery Based Treatment Approaches for Effective Management of Periodontitis. *Current Drug Therapy*. 2019;14(2):135-52. <https://doi.org/10.2174/1574885514666190103112855>.

- [14] Rams TE, Slots J. Local delivery of antimicrobial agents in the periodontal pocket. *Periodontology* 2000. 1996;10(1):139-59. <https://doi.org/10.1111/j.1600-0757.1996.tb00072.x>.
- [15] Lang NP, Lindhe J, editors. *Clinical periodontology and implant dentistry*, 2 Volume Set. John Wiley & Sons; 2015.
- [16] D'El Rey-Dantas FT, Feijó LS, Nogueira CE, Curcio BD. Doxycycline: a review regarding properties and clinical use in the equine species. *Science and Animal Health*. 2018;6(2):101-13.
- [17] Riond JL, Riviere JE. Pharmacology and toxicology of doxycycline. *Veterinary and human toxicology*. 1988;30(5):431.
- [18] Hamilton AR, Roberts M, Hutcheon GA, Gaskell EE. Formulation and antibacterial properties of clay mineral-tetracycline and-doxycycline composites. *Applied Clay Science*. 2019;179:105148. <https://doi.org/10.1016/j.clay.2019.105148>.
- [19] Rawla P, Raj JP. Doxycycline-induced acute pancreatitis: a rare adverse event. *Gastroenterology research*. 2017;10(4):244. doi: 10.14740/gr838w.
- [20] Craig WA. Pharmacokinetic/pharmacodynamic parameters: rationale for antibacterial dosing of mice and men. *Clinical infectious diseases*. 1998;26(1):1-10.
- [21] Michalova E, Novotna P, Schlegelova J. Tetracyclines in veterinary medicine and bacterial resistance to them. A review. *Veterinarni Medicina-UZPI (Czech Republic)*. 2004.
- [22] ALI IBRAHIM ES, Ismail S, Fetih G, Shaaban O, Hassanein K, Abdellah NH. Development and characterization of thermosensitive pluronic-based metronidazole in situ gelling formulations for vaginal application. *Acta pharmaceutica*. 2012;62(1):59-70. <https://doi.org/10.2478/v10007-012-0009-y>.
- [23] Escobar-Chávez JJ, López-Cervantes M, Naik A, Kalia Y, Quintanar-Guerrero D, Ganem-Quintanar A. Applications of thermo-reversible pluronic F-127 gels in pharmaceutical formulations. *Journal of Pharmacy & Pharmaceutical Sciences*. 2006;9(3):339-58.
- [24] Shriky B, Kelly A, Isreb M, Babenko M, Mahmoudi N, Rogers S, Shebanova O, Snow T, Gough T. Pluronic F127 thermosensitive injectable smart hydrogels for controlled drug delivery system development. *Journal of Colloid and Interface Science*. 2020;565:119-30. <https://doi.org/10.1016/j.jcis.2019.12.096>.
- [25] Oshagh M, Heidary S, Nazhvani AD, Koohepeima F, Hosseinabadi OK. Evaluation of histological impacts of three types of orthodontic fixed retainers on periodontium of rabbits. *Journal of Dentistry*. 2014;15(3):104.
- [26] Gupta R, Pandit N, Aggarwal S, Verma A. Comparative evaluation of subgingivally delivered 10% doxycycline hyclate and xanthan-based chlorhexidine gels in the treatment of chronic periodontitis. *J Contemp Dent Pract*. 2008;9(7):25-32.
- [27] Wennström JL, Newman HN, MacNeill SR, Killoy WJ, Griffiths GS, Gillam DG, Krok L, Needleman IG, Weiss G, Garrett S. Utilisation of locally delivered doxycycline in non - surgical treatment of chronic periodontitis: A comparative multi - centre trial of 2 treatment approaches. *Journal of clinical periodontology*. 2001;28(8):753-61. <https://doi.org/10.1034/j.1600-051X.2001.280806.x>.
- [28] Machion L, Andia DC, Lecio G, Nociti Jr FH, Casati MZ, Sallum AW, Sallum EA. Locally delivered doxycycline as an adjunctive therapy to scaling and root planing in the treatment of smokers: A 2 - year follow - up. *Journal of periodontology*. 2006;77(4):606-13. <https://doi.org/10.1902/jop.2006.050087>.
- [29] Bogren A, Teles RP, Torresyap G, Haffajee AD, Socransky SS, Wennström JL. Locally delivered doxycycline during supportive periodontal therapy: a 3-year study. *Journal of periodontology*. 2008;79(5):827-35. <https://doi.org/10.1902/jop.2008.070515>.
- [30] Madi M, Pavlic V, Samy W, Alagl A. The anti-inflammatory effect of locally delivered nano-doxycycline gel in therapy of chronic periodontitis. *Acta Odontologica Scandinavica*. 2018;76(1):71-6. <https://doi.org/10.1080/00016357.2017.1385096>.
- [31] Dumortier G, Grossiord JL, Agnely F, Chaumeil JC. A review of poloxamer 407 pharmaceutical and pharmacological characteristics. *Pharmaceutical research*. 2006;23(12):2709-28. <https://doi.org/10.1007/s11095-006-9104-4>.
- [32] Bezerra MM, Brito GA, Ribeiro RA, Rocha FA. Low-dose doxycycline prevents inflammatory bone resorption in rats. *Brazilian Journal of Medical and Biological Research*. 2002;35(5):613-6. <https://doi.org/10.1590/S0100-879X2002000500015>.
- [33] Bezerra MM, de Lima V, Alencar VB, Vieira IB, Brito GA, Ribeiro RA, Rocha FA. Selective cyclooxygenase - 2 inhibition prevents alveolar bone loss in experimental periodontitis in rats. *Journal of periodontology*. 2000;71(6):1009-14. <https://doi.org/10.1902/jop.2000.71.6.1009>.
- [34] Lohinai Z, Benedek P, Fehér E, Györfi A, Rosivall L, Fazekas Á, Salzman AL, Szabó C. Protective effects of mercaptoethylguanidine, a selective inhibitor of inducible nitric oxide synthase, in ligature - induced periodontitis in the rat. *British journal of pharmacology*. 1998;123(3):353-60. <https://doi.org/10.1038/sj.bjp.0701604>.
- [35] Xie R, Kuijpers-Jagtman AM, Maltha JC. Inflammatory responses in two commonly used rat models for experimental tooth movement: comparison with ligature-induced periodontitis. *archives of oral biology*. 2011;56(2):159-67. <https://doi.org/10.1016/j.archoralbio.2010.09.007>.
- [36] Woutersen RA, Jonker D, Stevenson H, Te Biesebeek JD, Slob W. The benchmark approach applied to a 28-day toxicity study with Rhodorsil Silane in rats: the impact of increasing the number of dose groups. *Food and Chemical Toxicology*. 2001;39(7):697-707. [https://doi.org/10.1016/S0278-6915\(01\)00015-1](https://doi.org/10.1016/S0278-6915(01)00015-1).

How to Cite this Article: Tamaddon AM, Saadati F, Khosropanah H, Nazhvani AL. Histologic Evaluation of New Doxycycline Gel Formulation for Subgingival Application in Experimental Periodontitis in Rats. *International Journal of Scientific Research in Dental and Medical Sciences*, 2020;2(4):107-114. doi: 10.30485/IJSRDMS.2020.247105.1084.