



Assessment of Therapeutic Indications of Surgical Navigation in Maxillofacial Surgery: A Systematic Review and Meta-analysis

Marzieh Jamali^a, Javad Jamali^{b,*}, Marzieh Ghasemi Vojoodi^a, Hashem Ahmadizadeh^c

^a School of Dentistry, Kermanshah University of Medical Sciences, Kermanshah, Iran

^b School of Dentistry, Shahed University of Medical Sciences, Tehran, Iran

^c School of Dentistry, Tehran University of Medical Sciences, Tehran, Iran

ARTICLE INFO

Article history:

Received 04 February 2020

Received in revised form 07 April 2020

Accepted 12 April 2020

Available online 23 April 2020

Keywords:

Surgery, oral

Therapeutics

Meta-analysis

ABSTRACT

Background and aim: Surgical navigation development and utilization in oral and maxilla-facial surgery quickly progressed in current years, and therapeutic indicators would be presented. The present systematic review and meta-analysis aimed at assessment of therapeutic indications of surgical navigation in maxillofacial surgery.

Materials and methods: MEDLINE, PubMed, Cochrane Library, Embase, ISI, google scholar has been utilized as the electronic databases for performing systematic literature until 2010 to 2019. Therefore, Endnote X9, which is one of the software programs in the market, has been utilized to manage the titles electronically. Searches were performed with keywords, “Orthognathic surgery”, “reconstruction surgery”, “maxillofacial surgery”, “Computer Assisted OR Computer methods”, “navigation” “Maxillofacial Injuries”, “Osteotomy, maxillary”. The current systematic review has been conducted about the primary issue of the PRISMA Statement–Preferred Reporting Items for Systematic Reviews and Meta-analysis.

Results: Heterogeneity found ($I^2 = 80.3\%$; $P=0.000$) and meta-analysis indicated a risk ratio of 0.187 (95% CI: 0.16– 0.21) (figure2). Surgical navigation could be considered a useful surgical tool. In orthognathic surgery, Heterogeneity found ($I^2 = 72.3\%$; $P=0.006$) and meta-analysis suggested a risk ratio of 0.10 (95% CI: 0.08–0.14). Finally, SN demonstrated to be a great tool to treat the diseases.

Conclusion: This study indicated SN could be a beneficial device for each intended indication.

1. Introduction

It is widely accepted that the surgical navigation system would match the surgical gear position like endoscope by making comparisons of the focuses in the respective field. This system would compute relationships between the patients' coordinate system and the image data-set.^[1] Nearly two decades ago, navigation was presented in the neck and head surgical operation.^[2] Created for the neurosurgical application, with the extending numbers of indication, the system moreover has been identified and accepted in the maxilla-facial surgery.^[3, 4] Computer tomography (CT) scan information set is analogous to a road map.^[5] The so-called road outline or naturally information set could be given via a few radiological techniques like the magnetic resonance imaging (MRI), positron emission tomography (PET) or as specified sometime recently CT. Moreover, the information would be loaded in a computer workstation and utilized for guiding the surgical procedure.^[4, 6] Thus, SN development and its utilization in oral and maxilla-facial surgeries have been quickly progressed in current decades, and consequently, therapeutic indicators would be presented.^[7] The present Systematic Review and Meta-

analysis aimed at Assessment of therapeutic indications of surgical navigation in maxillofacial surgery.

2. Materials and methods

Search strategy

MEDLINE, PubMed, Cochrane Library, Embase, ISI, google scholar has been utilized as the electronic data-bases for performing systematic literature until 2010 to 2019. Therefore, Endnote X9, which is one of the software programs in the market, has been utilized to manage the titles electronically. Searches were performed with keywords, “orthognathic surgery”, “reconstruction surgery”, “maxillofacial surgery”, “Computer Assisted OR Computer methods”, “navigation” “Maxillofacial Injuries”, “Osteotomy, maxillary”. The current systematic review has been conducted about the primary issue of the PRISMA Statement–Preferred Reporting Items for Systematic Reviews and Meta-analysis.^[8]

Selection criteria

Inclusion criteria

* Corresponding author. Javad Jamali

E-mail address: graywolf7814@gmail.com

School of Dentistry, Shahed University of Medical Sciences, Tehran, Iran

<http://doi.org/10.30485/IJSRDMS.2020.218633.1038>



1. Randomized controlled trials studies, controlled clinical trials, the prospective and retrospective cohort investigations.
2. The sample size was More than five patients.
3. In English

Exclusion criteria

1. In vitro studies, case studies, case reports and reviews.
2. No surgical outcomes.

Data Extraction and method of analysis

The following data were extracted from the research included: study, year, research design, size of the sample, range and mean of age, treatment, diagnosis, follow-up, control, X-ray. Outcomes were analyzed by meta-analysis. Finally, the Forest plots have been evaluated by Comprehensive Meta-analysis Stata V14.

3. Results

In Maxillofacial trauma surgery group 708 potentially related abstracts and topics have been discovered in the course of manual and electronic searches. Therefore, in the course of the first phase of the research selection, 543 studies have been ignored about titles and abstracts. In the next stage,

full-text papers of the rest 157 studies have been fully assessed. Then, 148 articles have been excluded due to the lack of fulfilment with the inclusion criteria. Ultimately, nine studies met the inclusion criteria of the present systematic review (Figure 1). In Orthognathic surgery group, 538 related abstracts and topics have been discovered in the course of manual and electronic searches. Therefore, in the course of the first phase of the research selection, 543 studies have been ignored about titles and abstracts. In the next stage, full-text papers of the rest 298 studies have been fully assessed. Then, 227 articles have been excluded due to the lack of fulfilment with the inclusion criteria. Ultimately, five studies met the inclusion criteria of the present systematic review (Figure 1). In Reconstructive surgery group, 603 related abstracts and topics have been searched in the course of manual and electronic searches. Therefore, in the course of the first phase of the research selection, 147 studies have been ignored about titles and abstracts. In the next stage, full-text papers of the rest 239 studies have been fully assessed. Then, 234 articles have been excluded due to the lack of fulfilment with the inclusion criteria. Ultimately, five studies met the inclusion criteria of the present systematic review (Figure 1). Table 1 showed individual studies in this meta-analysis.

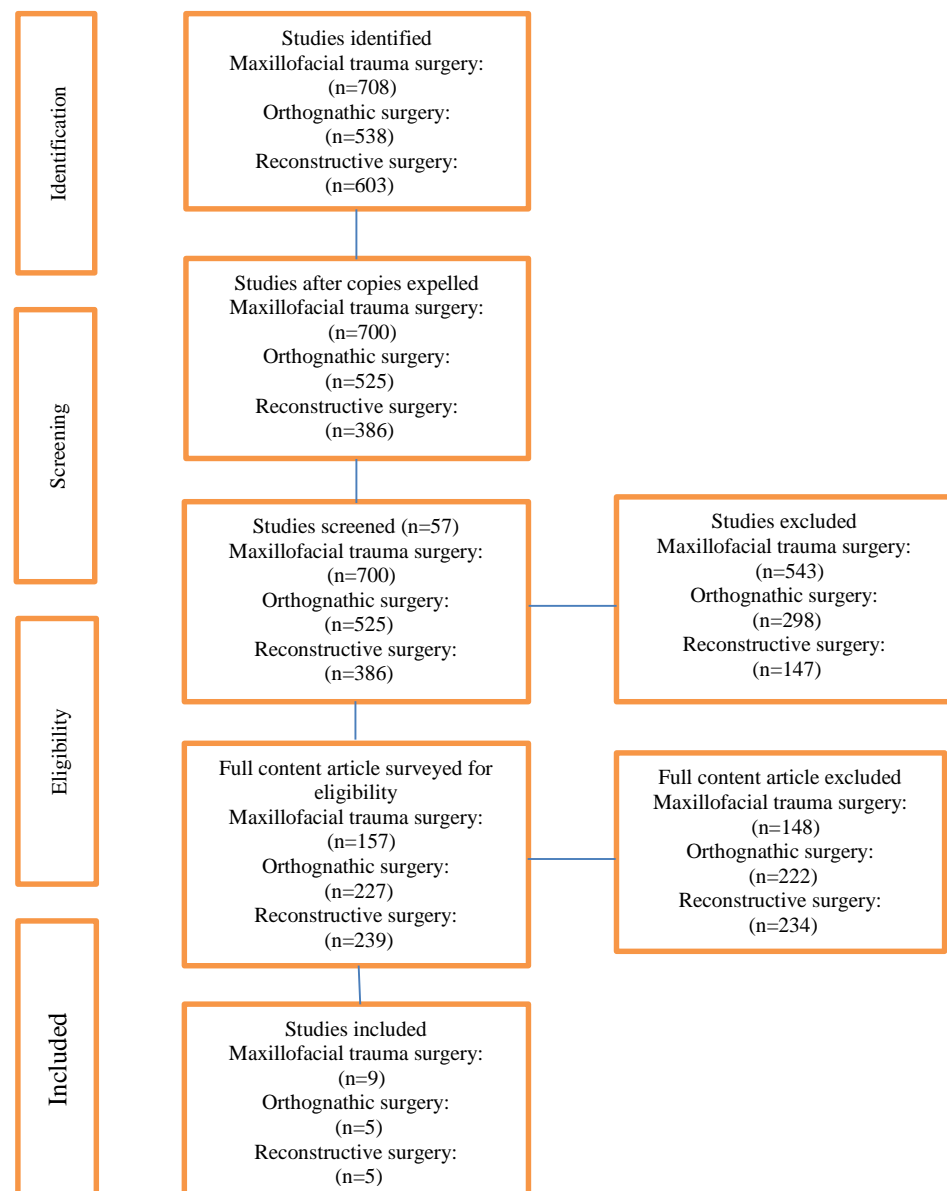


Figure 1. Study Attrition Diagram.

Table 1. Studies selected for systematic review and meta-analysis.

Group	Study/ years	Design	Sample size	Age (Mean)	Diagnosis	Treatment	Follow-up
Maxillofacial trauma surgery	He et al/2013 ^[9]	P	6	42.8	Deferred unilaterally fracture	Mirroring and ORIF	3 m
	Andrews et al/2013 ^[10]	R	8	29.2	Orbital fractures	ORI F	2w–6 m
	Zhang et al/2012 ^[11]	R	40	32	1-12 months post-traumatic defect	Mirroring and evaluation of harmoniousness facial	3-5 d 1–2y
	Markiewicz et al/2012 ^[12]	R	23	41.3	Post-traumatic defects	ORI F mirroring tech	NA
	Yu et al/2013 ^[13]	R	34	29	Zygomatic-orbital maxillary complex	Mirroring ORIF	5-65m
	Novelli et al/2014 ^[14]	R	11	32	Uni-lateral orbital fracture	Mirroring ORIF	NA
	Pierrefeu et al/2015 ^[15]	R	20	37.6	Uni-lateral midfacial fractures	Mirroring ORIF	NA
	Li et al/2014 ^[16]	P	23	31.43	Zygomatic arch fractures	OR	1.36 m
Orthognathic surgery	Sun et al/2014 ^[17]	P	17	NA	Not mentioned	Le Fort I	6, 10 w
	Zinser et al/2013 ^[18]	P	10	20.8	CI, CIII, VME	Le Fort I	6 m
	Zinser et al/2013 ^[19]	P	16	24	CIII	le Fort I	6 m
	Mazzoniet et al/2010 ^[20]	P	10	33.5	CIII, CIII, Hemimandibula r hypertrophy, OSAS	Lack of comprehensive information	1-6 m
	Li et al/2014 ^[21]	P	5	24.5	Not mentioned	Le Fort I+BSSO	3 d
Reconstructive surgery	Yu et al/2013 ^[22]	P	5	29	Uni-lateral ossifying fibroma, fibrous dysplasia	Block resection and reconstruction with HA prosthesis	12 -35 m
	Yu et al/2013 ^[13]	R	41	29	29 fibrous dysplasia, three cartilage/	Bone tumors, nine angulars hypertrophia/ recontouring, tumor resection	3-5 d
	Wang et al/2011 ^[23]	P	13	27.3	Uni-lateral fibrous dysplasia	Facial recontouring	6- 24 m
	Feichtinger et al/2010 ^[24]	P	6	58.6	ACC,SCC reconstruction	Five neck node dissection, tumor resection, immediate	NA
	Zhang et al/2015 ^[25]	R	10	42.1	Orbital floor defects after maxillectomy	Mirroring, reconstruction with titanium mesh	7 m
Guo et al/2015 ^[26]	R	42	42.27	Recurrent malignant in Fra temporal fossa tumors	Resection	13 m	

P: Prospective. R: Retrospective. M: months. W: week. D: days. Y: years. NA: not report. Us: Unaffected side. Cg: control group. Ni: non-invasive.

Table 2. Outcome of Studies.

Study/ years	Results(mm)	control	Registration strategy	Postoperative control strategy	X-ray
He et al/2013 ^[9]	1.28 width/1.22eminence +1.24/-1.4	Us	Non-invasive/bone surface marking	Width and Eminence	CT
Andrews et al/2013 ^[10]	1-2 mm accurate anatomic reconstruction	Us	Ni	Intraoperative control of plate position	CT
Zhang et al/2012 ^[11]	1mm average deviation	Pre-op CT	35 invasive/5 Ni	Super-imposition of x-rays	CT
Markiewicz et al/2012 ^[12]	5.1cm ³ and 4.1 mm	Us	Ni	Globe volume/ projection	CT
Yu et al/2013 ^[13]	1.57±0.29 mm	Pre-op CT	Invasive	5 points pre and post-op x rays	CT
Novelli et al/2014 ^[14]	1.3 mm 0.21cm	Pre-op CT	Invasive &Ni	Pre and post-op x rays	CT
Pierrefeu et al/2015 ^[15]	0.12 mm overall mean difference	Pre-op plan	Invasive and Ni	Planned versus final outputs	CT, CB CT
Li et al/2014 ^[16]	17.65mm pre-op versus 38.91mm post-op	Pre-op plan	Ni	Pre-op versus post-op MMO	CT

Sun et al/2014 ^[17]	0.44±0.35 (p0.82); 0.50±0.35 (p0.85); 0.56±0.36(p0.81)/ intraobserver (p=0.93;p=0.69;p=0.63)	Sagittal, vertical, Mediolateral movements	Ni	Edge of the upper incisor point	CBCT
Zinser et al/2013 ^[18]	0.61;p<0.05	Post-op versus pre-op plan	Ni	13hard tissues Seven soft tissues	CBCT /3D ceph
Zinser et al/2013 ^[19]	<0.61;p>0.05	Post-op versus pre-op plan	Ni	13hard tissues Seven soft tissues	CBCT /3D ceph
Mazzoniet et al/2010 ^[20]	86% reproducibility	Post-op vs. pre-op plan	Invasive	Surface overlapping	CBCT
Li et al/2014 ^[21]	0.72-1.12 vertically; 0.56-0.94 axially; 0.39-.58 horizontally	Vertical, horizontal, axial directions	Ni	Six landmarks & 3planes	CT
Yu et al/2013 ^[22]	1.87±0.45	Contra lateral side	Ni	Five anatomical landmark	CT
Yu et al/2013 ^[13]	1.42±.21/1.85±0.4 7/1.49±0.26	Super-imposition of VSP & postop CT	Ni	Five anatomical landmarks	CT
Wang et al/2011 ^[23]	2 mm mean dis	Contra lateral side	Invasive	Unaffected	CT
Feichtinger et al/2010 ^[24]	Descriptive data for each patient	Frozen sections	Ni	None	PET /CT
Zhang et al/2015 ^[25]	Globe projection: 15.91±1.8mm vs. 16.24±2.24mm Orbital volume: 26.01±1.28ml vs. 25.27±1.89ml	Us	NA	Globe projection & orbital volume	CT
Guo et al/2015 ^[26]	-536.36* vs. 503.87ml**; P=0.814 No significant differences between*and**	Cg	Ni	Operation time, Bleeding volume, Tumor size, Surgical approach, Complications, Follow up survey, outcome, survival analysis	CT

Maxillofacial trauma surgery

Nine studies (3 prospective and 6 retrospective) were included, Number of patient ranged from 6 to 40 in all 182 patient, with the mean age equal to 34.41 years and range, 29-43 years. Follow-up period ranged from 3 days to

65 months. Heterogeneity found (I2 = 80.3%; P=0.000) and meta-analysis revealed a risk ratio of 0.187 (95% CI: 0.16–0.21) (Figure 2). Surgical navigation might be regarded as one of the beneficial surgical tools.

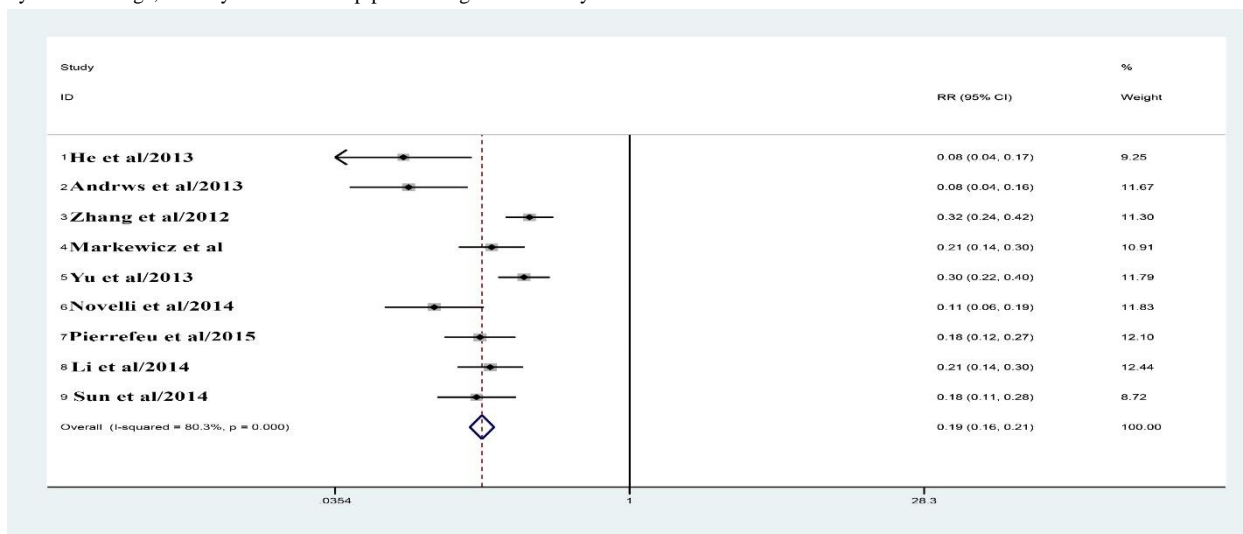


Figure 2. Forest plots with regard to the surgical navigation and trauma surgeries.

Heterogeneity chi-squared = 40.55 (df. = 8) p=0.000.
I-squared (variation in the RR attributed to heterogeneity) = 80.3%.
RR Test = 1:z= 23.91 p=0.000.

Orthognathic surgery

Five studies (5 prospective) were included, Number of patient ranged from 5 to 16 in all 46 patient, with the mean age equal to 26.36 years and ranges of, 20-43 years. Follow-up period ranged from 3 days to 6 months.

Heterogeneity found (I2 = 72.3%; P=0.006) and meta-analysis revealed a risk ratio equal to 0.10 (95% CI: 0.08–0.14) (Figure 3). Finally, SN demonstrated that is a great tool to treat the diseases.

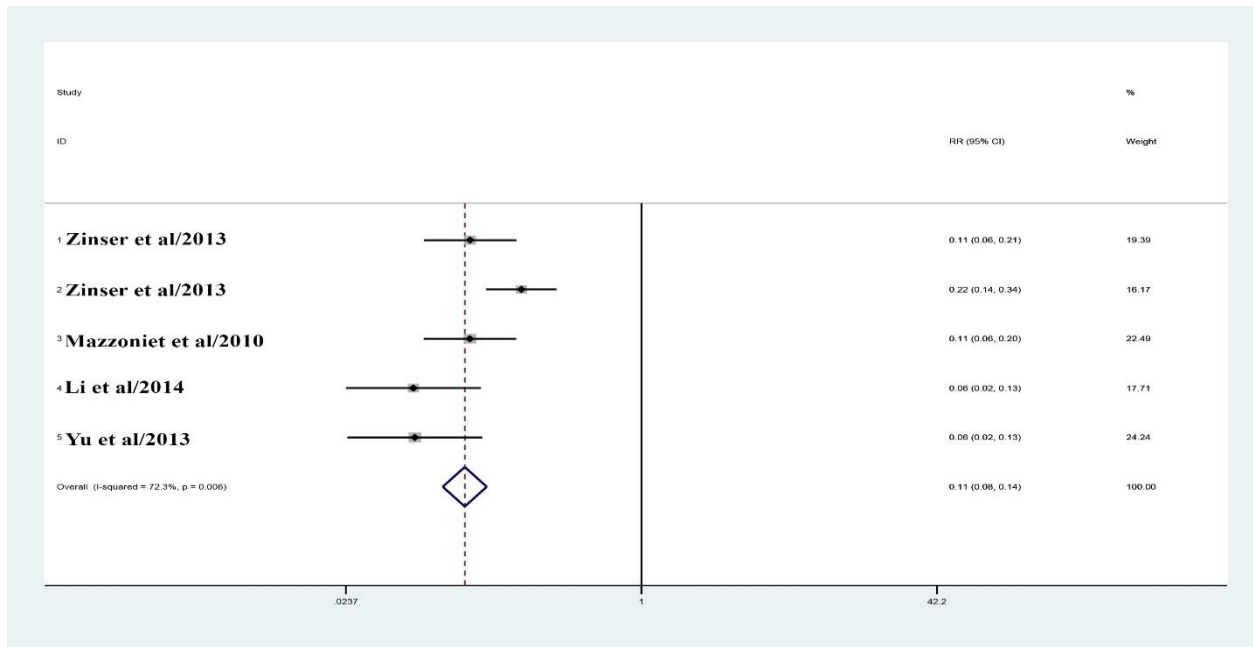


Figure 3. Forest plots with regard to the surgical navigation and ortho-gnathic surgeries.

Heterogeneity chi-squared = 14.44 (df. = 4) p=0.006.

I-squared (variation in RR attributed to heterogeneity) = 72.3%.

RR Test=1: z = 15.74 p=0.000.

Reconstructive surgery

Five studies (2 prospective and 3 retrospective) were included, Number of patient ranged from 6 to 42 in all 112 patient , with the mean age equal to 38.85 years and ranges from, 27-59 years. The follow up course has been in a range between 3 days and 24 months. Heterogeneity found (I²=87.6%,

P=0.000) and the meta-analysis showed the risk ratio of 0.26 (95% CI: 0.22–0.31) (Figure 4). Finally, it has been proved that SN is a great tool to treat the diseases.

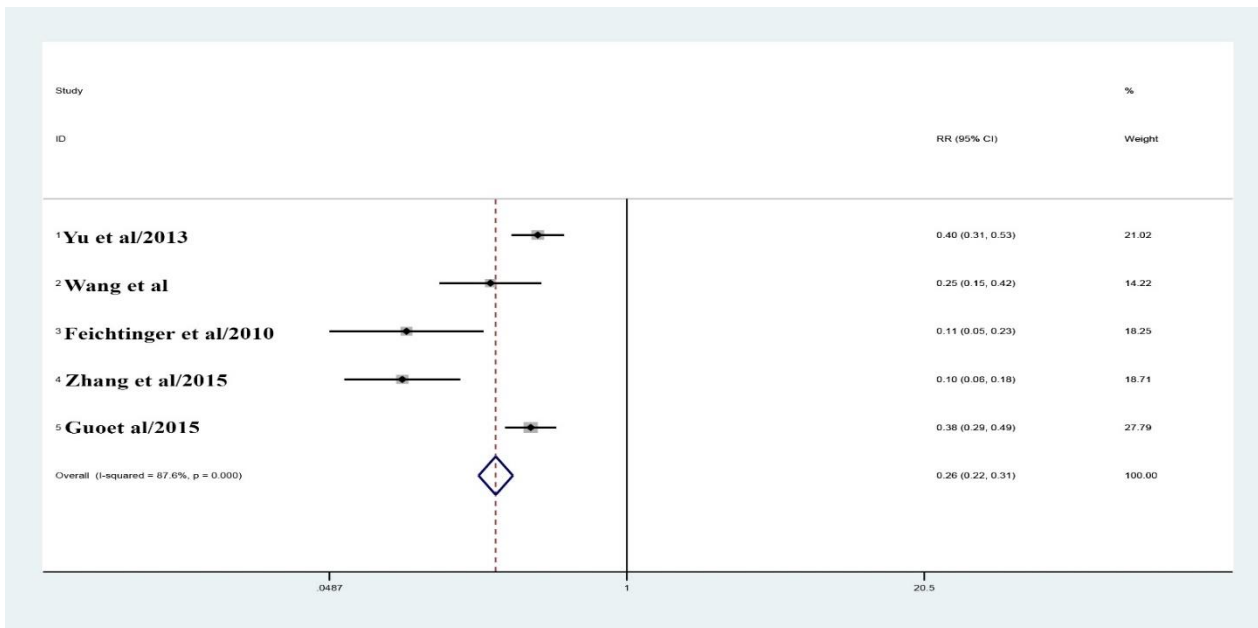


Figure 4. Forest plots with regard to the surgical navigation, cancer, and re-constructive surgeries.

Heterogeneity chi-squared = 32.21 (df. = 4) p=0.000.

I-squared (variation in the RR attributed to heterogeneity) = 87.6%.

RR test = 1: z = 14.99 p = 0.000.

4. Discussion

This meta-analysis and systematic review examined applications of surgical navigation with respect to different, popular indicators, treatment options, and results in maxilla-facial surgery. Studies hypothesized that current improvement in the computer-assisted surgery has determined the quality of SN as an important expansion to the surgical tool-box.^[27, 28] Our discoveries demonstrate SN as a valuable surgical device. Moreover, results showed that SN is an amazing tool to evaluate the treatments. In addition, contemporary distributions suggested SN may be utilized to achieve the objectives of the study for discovering clinical superiorities.^[18, 29] Even though researchers performed the initial endeavors to utilize SN methods in the maxilla-facial surgery, a few key challenges should be also resolved. However, technical restrictions like un-altered DICOM data significantly made actions for comparing symmetry over the mid-line a hard job. Moreover, such restrictions constrained development of additional arrangements like CAD/CAM.^[7, 30, 31] A few variables, like the computer algorithm accuracy, the determination of CT information set achieved as well as the information registration precision would be critical and could influence accuracy of the navigation system.^[32] With regard to the navigation system, a few diverse firms have been represented in the included considers, and each given acceptable outcome.^[33, 34] Therefore, treating the orbital fractures, particularly the complex fractures could regularly be highly difficult, indeed for skilful surgeons. SN could be a very supportive device while addressing these issues. In fact, it appears to propose patient-specific implants (PSI) as another step for assist the advancement of the treatment regime.^[35] Benefits are advertised with SN for surgeons and patients; therefore, this would require the staff individuals of the surgical group to have a great integration into the handle. Thus, technical prerequisites would be highly demanding and laborious that itself make an alter in the mind-set alluring for the staff as the group. Consequently, positive perspectives should be dealt with while doing the orthognathic surgery. Azarmehr t al.^[7] in a systematic review, the SN emergence and its utilization in maxillofacial and oral surgeries. Result showed, SN would be highly encouraging expansion to the surgical tool-kit and the surgical planning specifications in a 3D virtual context and implementations with the real time guidance could remarkably enhance accuracy. He et al.^[9] showed surgical navigation could make easy the navigation planning for surgical operations and prevent complicated protocols necessary for creating surgical templates. Zhang et al.^[11] demonstrated that the navigation-guided correction for treating the mid-facial post-traumatic deformity could be viewed as one of the perfect and worthwhile options for such a potent complex process. In addition, results of Markiewicz et al.^[12] suggested effectiveness of the orbital re-construction via the intra-operative navigation in the establishment of the normal orbital volumes and globe projection in the post-traumatic and post-ablative defect. Thus, it would restore the orbit and globe to the pre-traumatic and pre-ablative condition. Also Yu et al.^[13] showed that in addition to prove opportunities for performing the pre-operative planning, surgical simulations as well as the post-operative predictions, computer-assisted navigation showed to be valuable for the improvement of the maxilla-facial surgery precision, reduction of the operation risks as well as the post-surgical morbidities, and finally the restoration of the facial symmetry. Therefore, it has been viewed as one of the worthwhile techniques in such potentially complex operations. Thus, this comprehensively introduced protocol incorporate each new technology for planning virtual reconstruction surgeries. Hence, outputs achieved by experiences would be largely attractive, pursuing the proposed way.^[14] Pierrefeu et al.^[15] evaluated a certain navigation system precision and integrated “mirroring” computational planning for treating the mid-facial

fractures via making comparison with the actual post-operative 3D images, they find that the post-traumatic mid-facial reconstructions could be precisely estimated and anticipated through a certain navigation system, which integrated the “mirroring” computational planning for a majority of the patients.

5. Conclusion

This review indicated SN could be one of the beneficial tools for each indication. Considering coordination SN as a portion of the therapeutic regime, it should be noted that the considerable surgical expertise could not be agreed. However, a learning curve has been found and monetary issues should be managed; however, maxilla-facial surgeons reported SN could be a highly useful device as the experts in the field learned the methods adequately. Moreover, SN could be utilized as an instrument for assessment and investigations.

Conflict of Interest

The authors declared that there is no conflict of interest.

Acknowledgments

This research received no specific grant from any funding agency in the public, commercial, or not-for-profit sectors.

References

- [1] Waelkens P, van Oosterom MN, van den Berg NS, Navab N, van Leeuwen FW. Surgical navigation: an overview of the state-of-the-art clinical applications. *Radioguided Surgery*: Springer; 2016. p. 57-73. https://doi.org/10.1007/978-3-319-26051-8_4.
- [2] Wimmer W, Gerber N, Weber S, Nolte LP, Caversaccio M. 12 Jahre Computer-Aided Surgery around the Head. *HNO*. 2016 1;64(9):625-9. <https://doi.org/10.1007/s00106-016-0156-4>.
- [3] Kumar V, Chaudhry K, Gour S, Aeran H, Agarwal A. Advent of surgical navigation in oral and maxillofacial surgery and application of different navigational systems in various surgical procedures: a review. *J Interdiscipl Med Dent Sci*. 2018;6(225):2. DOI:10.4172/2376-032X.1000225.
- [4] Kumar V, Gour S, Chaube RK, Chaube RK, Gupta A, Chaube SK. Surgical Navigation in Oral and Maxillofacial Surgery: A Review. *Clin Res Open Access*. 2018;4(2). DOI: <http://dx.doi.org/10.16966/2469-6714.136>.
- [5] Bell RB. Computer planning and intraoperative navigation in orthognathic surgery. *Journal of oral and maxillofacial surgery*. 2011;69(3):592-605. DOI:<https://doi.org/10.1016/j.joms.2009.06.030>.
- [6] Coronel MM, Farag I, Shallik NA. Computer-Assisted 3D Reconstruction in Oral and Maxillofacial Surgery. *Virtual Endoscopy and 3D Reconstruction in the Airways*: Springer; 2019. p. 67-84. https://doi.org/10.1007/978-3-030-23253-5_7.
- [7] Azarmehr I, Stokbro K, Bell RB, Thygesen T. Surgical navigation: a systematic review of indications, treatments, and outcomes in oral and maxillofacial surgery. *Journal of Oral and Maxillofacial Surgery*. 2017;75(9):1987-2005. <https://doi.org/10.1016/j.joms.2017.01.004>.
- [8] Panic N, Leoncini E, De Belvis G, Ricciardi W, Boccia S. Evaluation of the endorsement of the preferred reporting items for systematic reviews and meta-analysis (PRISMA) statement on the quality of published systematic review and meta-analyses. *European Journal of Public Health*. 2013;8(12):e83138. <https://doi.org/10.1093/eurpub/ckt124.018>.

- [9] He Y, Zhang Y, An JG, Gong X, Feng ZQ, Guo CB. Zygomatic surface marker-assisted surgical navigation: a new computer-assisted navigation method for accurate treatment of delayed zygomatic fractures. *Journal of Oral and Maxillofacial Surgery*. 2013;71(12):2101-14. <https://doi.org/10.1016/j.joms.2013.07.003>.
- [10] Andrews BT, Surek CC, Tanna N, Bradley JP. Utilization of computed tomography image-guided navigation in orbit fracture repair. *Laryngoscope*. 2013;123(6):1389-93. DOI: 10.1002/lary.23729.
- [11] Zhang S, Gui H, Lin Y, Shen G, Xu B. Navigation-guided correction of midfacial post-traumatic deformities (Shanghai experience with 40 cases). *Journal of oral and maxillofacial surgery*. 2012;70(6):1426-33. <https://doi.org/10.1016/j.joms.2011.03.068>.
- [12] Markiewicz MR, Dierks EJ, Bell RB. Does intraoperative navigation restore orbital dimensions in traumatic and post-ablative defects? *Journal of Cranio-Maxillofacial Surgery*. 2012;40(2):142-8. <https://doi.org/10.1016/j.jcms.2011.03.008>.
- [13] Yu H, Shen SG, Wang X, Zhang L, Zhang S. The indication and application of computer-assisted navigation in oral and maxillofacial surgery—Shanghai's experience based on 104 cases. *Journal of Cranio-Maxillofacial Surgery*. 2013;41(8):770-4. <https://doi.org/10.1016/j.jcms.2013.01.016>.
- [14] Novelli G, Tonellini G, Mazzoleni F, Bozzetti A, Sozzi D. Virtual surgery simulation in orbital wall reconstruction: integration of surgical navigation and stereolithographic models. *Journal of Cranio-Maxillofacial Surgery*. 2014;42(8):2025-34. <https://doi.org/10.1016/j.jcms.2014.09.009>.
- [15] Pierrefeu A, Terzic A, Volz A, Courvoisier D, Scolozzi P. How accurate is the treatment of midfacial fractures by a specific navigation system integrating “mirroring” computational planning? Beyond mere average difference analysis. *Journal of Oral and Maxillofacial Surgery*. 2015;73(2):315. e1-. e10. <https://doi.org/10.1016/j.joms.2014.09.022>.
- [16] Li Z, Yang RT, Li ZB. Applications of computer-assisted navigation for the minimally invasive reduction of isolated zygomatic arch fractures. *Journal of Oral and Maxillofacial Surgery*. 2015;73(9):1778-89. <https://doi.org/10.1016/j.joms.2015.03.033>.
- [17] Sun Y, Luebbbers HT, Agbaje JO, Lambrichts I, Politis C. The accuracy of image-guided navigation for maxillary positioning in bimaxillary surgery. *Journal of Craniofacial Surgery*. 2014;25(3):1095-9. doi: 10.1097/SCS.0000000000000633.
- [18] Zinser MJ, Sailer HF, Ritter L, Braumann B, Maegele M, Zöller JE. A paradigm shift in orthognathic surgery? A comparison of navigation, computer-aided designed/computer-aided manufactured splints, and “classic” intermaxillary splints to surgical transfer of virtual orthognathic planning. *Journal of oral and maxillofacial surgery*. 2013;71(12):2151. e1-. e21. <https://doi.org/10.1016/j.joms.2013.07.007>.
- [19] Zinser MJ, Mischkowski RA, Dreiseidler T, Thamm OC, Rothamel D, Zöller JE. Computer-assisted orthognathic surgery: waferless maxillary positioning, versatility, and accuracy of an image-guided visualisation display. *British Journal of Oral and Maxillofacial Surgery*. 2013;51(8):827-33. <https://doi.org/10.1016/j.bjoms.2013.06.014>.
- [20] Mazzoni S, Badiali G, Lancellotti L, Babbi L, Bianchi A, Marchetti C. Simulation-guided navigation: a new approach to improve intraoperative three-dimensional reproducibility during orthognathic surgery. *Journal of Craniofacial Surgery*. 2010;21(6):1698-705. doi: 10.1097/SCS.0b013e3181f3c6a8.
- [21] Li B, Zhang L, Sun H, Shen SG, Wang X. A new method of surgical navigation for orthognathic surgery: optical tracking guided free-hand repositioning of the maxillomandibular complex. *Journal of Craniofacial Surgery*. 2014;25(2):406-11. doi: 10.1097/SCS.0000000000000673.
- [22] Yu H, Wang X, Zhang S, Zhang L, Xin P, Shen S. Navigation-guided en bloc resection and defect reconstruction of craniomaxillary bony tumours. *International journal of oral and maxillofacial surgery*. 2013;42(11):1409-13. <https://doi.org/10.1016/j.ijom.2013.05.011>.
- [23] Wang X, Lin Y, Yu H, Cheng AH, Sun H, Wang C, Shen G. Image-guided navigation in optimizing surgical management of craniomaxillofacial fibrous dysplasia. *Journal of Craniofacial Surgery*. 2011;22(5):1552-6. doi: 10.1097/SCS.0b013e31822e5d3d.
- [24] Feichtinger M, Pau M, Zemann W, Aigner RM, Kärcher H. Intraoperative control of resection margins in advanced head and neck cancer using a 3D-navigation system based on PET/CT image fusion. *Journal of Cranio-Maxillofacial Surgery*. 2010;38(8):589-94. <https://doi.org/10.1016/j.jcms.2010.02.004>.
- [25] Zhang WB, Mao C, Liu XJ, Guo CB, Yu GY, Peng X. Outcomes of orbital floor reconstruction after extensive maxillectomy using the computer-assisted fabricated individual titanium mesh technique. *Journal of Oral and Maxillofacial Surgery*. 2015;73(10):2065. e1-. e15. <https://doi.org/10.1016/j.joms.2015.06.171>.
- [26] Guo R, Guo YX, Feng Z, Guo CB. Application of a computer-aided navigation technique in surgery for recurrent malignant infratemporal fossa tumors. *Journal of Craniofacial Surgery*. 2015;26(2):e126-e32. doi: 10.1097/SCS.0000000000001350.
- [27] Scolozzi P, Terzic A. “Mirroring” computational planning, navigation guidance system, and intraoperative mobile C-arm cone-beam computed tomography with flat-panel detector: A new rationale in primary and secondary treatment of midfacial fractures? *Journal of oral and maxillofacial surgery*. 2011;69(6):1697-707. DOI:<https://doi.org/10.1016/j.joms.2010.07.049>.
- [28] Stuck B, Hülse R, Barth T. Intraoperative cone beam computed tomography in the management of facial fractures. *International journal of oral and maxillofacial surgery*. 2012;41(10):1171-5. <https://doi.org/10.1016/j.ijom.2012.06.006>.
- [29] Jeon J. Digital technology in orthognathic surgery: virtual surgical planning and digital transfer. *Korean Association of Oral and Maxillofacial Surgeons*; 2019. <https://doi.org/10.5125/jkaoms.2019.45.5.231>.
- [30] Gong X, He Y, An J, Yang Y, Huang X, Liu M, et al. Application of a computer-assisted navigation system (CANS) in the delayed treatment of zygomatic fractures: a randomized controlled trial. *Journal of Oral and Maxillofacial Surgery*. 2017;75(7):1450-63. <https://doi.org/10.1016/j.joms.2016.10.001>.
- [31] Sukegawa S, Kanno T, Furuki Y. Application of computer-assisted navigation systems in oral and maxillofacial surgery. *Japanese Dental Science Review*. 2018;54(3):139-49. <https://doi.org/10.1016/j.jdsr.2018.03.005>.
- [32] Dong Y, Zhang C, Ji D, Wang M, Song Z. Regional-surface-based registration for image-guided neurosurgery: effects of scan modes on registration accuracy. *International journal of computer assisted radiology and surgery*. 2019;14(8):1303-15. <https://doi.org/10.1007/s11548-019-01990-6>.
- [33] Roccia F, Zavattero E. From Theory to Theatre: Virtual Planning and Intraoperative Navigation in Oral and Maxillofacial Surgery. *Cosmetol & Oro Facial Surg*. 2017;3:e103.

- [34] Chen X, Xu L, Sun Y, Politis C. A review of computer-aided oral and maxillofacial surgery: planning, simulation and navigation. *Expert review of medical devices*. 2016;13(11):1043-51. <https://doi.org/10.1080/17434440.2016.1243054>.
- [35] Rana M, Chui CH, Wagner M, Zimmerer R, Rana M, Gellrich N-C. Increasing the accuracy of orbital reconstruction with selective laser-melted patient-specific implants combined with intraoperative navigation. *Journal of Oral and Maxillofacial Surgery*. 2015;73(6):1113-8. <https://doi.org/10.1016/j.joms.2015.02.014>.

How to Cite this Article: Jamali M, Jamali J, Ghasemi Vojoodi M, Ahmadizadeh H. Assessment of Therapeutic Indications of Surgical Navigation in Maxillofacial Surgery: A Systematic Review and Meta-analysis. *International Journal of Scientific Research in Dental and Medical Sciences*. 2020;2(2):29-36. doi: 10.30485/IJSRDMS.2020.218633.1038.