



International Journal of Scientific Research in Dental and Medical Sciences

www.ijstdms.com



Preoperative Predictors and Ossicular Involvement in Chronic Otitis Media

Mohan Ananthula ^a, Soumya Singh ^{b,*}

^a Shree Krishna ENT Care and Hearing Centre, Sircilla, India

^b Department of Otorhinolaryngology, Amltas Institute of Medical Sciences, Madhya Pradesh, India

ARTICLE INFO

Article history:

Received 07 January 2024

Received in revised form 26 February 2024

2024

Accepted 05 March 2024

Available online 09 March 2024

Keywords:

Ear Ossicles

Hearing Loss

Otitis Media

ABSTRACT

Background and aim: Ossicular chain disease may occur in chronic otitis media (COM). Certain preoperative factors can predict this ossicular disruption, which can be confirmed intraoperatively and can prognosticate the surgical outcome in COM.

Material and methods: One hundred and forty-five patients of COM were recruited in this prospective study, and ossicular chain status in different types of COM was studied and compared. All the variables were noted, and statistical analysis was performed using IBM (International Business Machines) SPSS (Statistical Package for the Social Studies) Statistics 26 software.

Results: Intra-operatively ossicular chain defects were detected in 48(33.1%) cases. Of these, Incus (32.41%) was found to be the most common, followed by malleus (20.7%) and less commonly stapes (9.66%). The most common type of ossicular erosions seen in our study was the M+ Ip S+ (Malleus intact, Incus partially eroded, and Stapes intact) type seen in 13 cases. The mean hearing loss was higher (54.96dB) in patients with ossicular erosion compared with patients without ossicular erosion (41.30dB).

Conclusions: Moderate to severe hearing loss and air-bone gap of >40dB and active squamosal type of COM (cholesteatoma) are the important predictors of ossicular chain disease in COM. Ossicular chain disruption can be classified according to the involvement of different ossicles and can help to prognosticate the postoperative outcome.

1. Introduction

According to WHO, the global burden of illness from COM (chronic otitis media) involves 65–330 million individuals, 60% of whom (39–200 million) suffer from significant hearing impairment.^[1] In India, the overall prevalence rate is 46 and 16 per thousand in rural and urban populations, respectively. The continuity of the ossicular chain and the tympanic membrane is vital for impedance-matching in the middle ear. Both types of COM may lead to erosion of the ossicular chain, which is much greater in cases of squamosal COM.^[2] The long process of incus, stapes crura, the body of the incus, and manubrium are involved in the order of frequency.^[3,4] It has been speculated that chronic inflammation causes the release of many cytokines such as TNF, causing hypervascularisation, osteoclast activation, and bone absorption, which ultimately leads to ossicular damage in COM.^[5] Disruption of the ossicular chain can result in moderate-severe hearing loss (approximately 60 dB).^[7,8] Discontinuity of the ossicular chain is typically confirmed only at surgery, but modalities that may be useful in ascertaining ossicular integrity are preoperative HRCT (High-resolution computed tomography) scan of the temporal bone and scanning Electron Microscopy.^[9] In this study, we intend to assess ossicular chain status in patients with COM (both mucosal and squamosal) and also to identify the predictors of

ossicular erosion and association of hearing loss with the type of ossicular defect in these patients.

2. Material and methods

This Prospective observational study was done in the Department of Otorhinolaryngology at our institute for 2 years (June 2016- May 2018). The study was approved by the Ethical Committee of Gaja Raja Medical College, Gwalior, with approval number (16/EC/GRMC/2016). Detailed history with detailed ear examination was done in all the recruited patients of COM. Preoperative investigations, including routine blood investigations, Pure Tone Audiometry (PTA), X-ray mastoid in Schuller's view, and HRCT temporal bone (in cases of squamosal COM only), were performed in all the patients. All patients of COM mucosal inactive, squamosal active, and inactive aged between 15 and 60 years were included in our study. Patients with any comorbidities due to which they are rendered unfit for surgical intervention, patients having A-B gap <20 dB and more sensory neural component in audiological profile, squamosal cases which underwent radical mastoidectomy, cases which showed ossicular fixation as examined intraoperatively were excluded from the study.

* Corresponding author. *Soumya Singh*

E-mail address: drsoumyasengar@gmail.com

Department of Otorhinolaryngology, Amltas Institute of Medical Sciences, Madhya Pradesh, India

<https://doi.org/10.30485/IJSDMS.2024.434505.1554>



Prediction of ossicular chain disease

The presence of any of the parameters was taken as a positive predictor for ossicular chain discontinuity, and based on the predictions we made, intraoperative confirmation of ossicular discontinuity was done (Fig. 1).

1. PTA (Pure Tone Audiometry) showing moderate to severe hearing loss or air-bone gap >40dB.
2. Squamosal COM disease (both active and inactive).

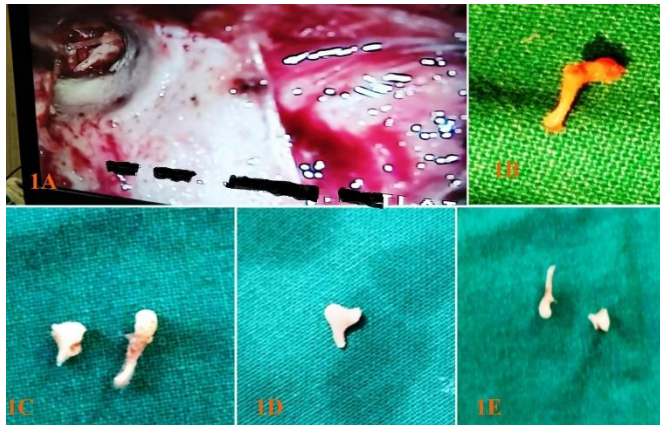


Fig. 1. (A) Intraoperative picture of ossicular erosion during surgery. 1 (B, C, D, E), Retrieved damaged ossicles, which were used for ossicular reconstruction.

Adequate surgical intervention (cortical mastoidectomy with or without ossicular reconstruction for mucosal disease, modified radical mastoidectomy with ossicular reconstruction) was performed depending on the extent of disease and ossicular erosion and type of ossicular discontinuity was observed and documented intraoperatively. We documented ossicular erosion in a simpler format based on the condition of all three ossicles intraoperatively. Intact (+), eroded [partial (p) or complete (-) or absent (-)] status were marked for each ossicle in every patient. Analysis of quantitative variables was done using %, mean, standard deviation, and unpaired t-test, and qualitative data was analyzed using the chi-square test or Fisher exact test. Statistical analysis was performed with IBM SPSS Statistics 26 software.

3. Results

The demographic and clinical characteristics of the study population are noted in Table 1. Incidence of COM is higher in females- 93 patients (64.14%) than in males- 52 patients (35.86%) with a sex ratio of 1.79. Of these 145 patients, 63 (43.45%) had left ear disease, 60 (41.38%) had right side disease, and bilateral disease was seen in 22 (15.17%) of total patients. Ear discharge (97.2%) and hearing loss (97.9%) are common complaints in all patients of chronic otitis media. Bilateral hearing loss was presented in 24 (16.55%) of patients, with left ear symptoms in 60 (41.38%) and right ear in 58 (40%) patients. Of the total 145 patients studied, 97 patients (66.9%) had an intact ossicular chain, and 48 patients (33.1%) had ossicular chain disease leading to discontinuity. Of these, incus (32.41%) was found to be the most commonly involved ossicle, followed by malleus (20.7%), and the less commonly involved ossicle was stapes (9.66%), as mentioned in Table 1.

Table 1. Shows the clinical characteristics of the study population.

Characteristics	Values
1. Age (Years)	Mean- 46.8 years
	51-60 yrs age- 41 (28.28%) 41-50 yrs age- 26 (17.9%)
2. Gender-	Male- 52 (35.86%) Female- 93 (4.14%)
	Ear discharge- 141 (97.2%) Hearing loss- 142 (97.9%) Tinnitus- 41(28.3%) Ear pain- 17 (11.7%) Giddiness- 19 (13.1%) Facial weakness-1 (0.7%)
3. Symptoms	1. Malleus-
	Intact - 115 (79.31%) Eroded - 25 (17.24%) Absent - 5 (3.45%)
	2. Incus-
4. Ossicular chain status	Intact - 98 (67.59%) Eroded - 29 (20%) Absent - 18 (12.4%)
	3. Stapes-
	Intact - 131(90.34%) Eroded - 13 (8.97%) Absent - 1 (.69%)

On oto-microscopy, radiological assessment, and intraop middle ear microscopic examination, the presence of cholesteatoma was seen in 21 patients in whom all the cases had ossicular chain disease(100%). Thirty-one patients had squamosal disease, and all of them had some amount of ossicular disease. One hundred fourteen patients presented with mucosal disease, of which 17 (12.28%) showed ossicular erosions (Table 2).

Table 2. Showing ossicular chain disease in types of com and with cholesteatoma.

Type of COM and Cholesteatoma	Total no. of cases	Cases with OCD (Ossicular chain disease)
Mucosal Disease	114	17(12.28%)
Squamosal inactive Disease	31	31 (100%)
Squamosal active (Cholesteatoma present)	21	21 (100%)

Ossicular chain status was studied, and the most common type of ossicular erosions seen in our study is M+ Ip S+ type, seen in 13 cases, and the next most common type is Mp Ip S+ type, seen in 12 cases (Table 3). On audiometric evaluation, patients having moderate to profound type of hearing loss with an A-B gap of more than 40 dB were consistently showing the presence of ossicular chain disease. Of the total cases of ossicular disease, which is seen in 48 cases, 39 cases (81.25%) had hearing loss ranging from moderate, moderate to severe, severe, and profound hearing loss (Table 4).

Table 3. New proposed classification of ossicular chain defects.

Malleus	Incus	Stapes	Cases
Intact(M+)	Intact(I+)	Intact(S+)	97
Intact(M+)	Eroded(Ip)	Intact(S+)	13
Intact(M+)	Absent(I-)	Intact(S+)	1
Intact(M+)	Intact(I+)	Eroded(Sp)	1
Intact(M+)	Eroded(Ip)	Eroded(Sp)	2
Intact(M+)	Absent(I-)	Eroded(Sp)	1
Absent(M-)	Absent(I-)	Intact(S+)	2
Absent(M-)	Absent(I-)	Eroded(Sp)	3
Eroded(Mp)	Absent(I-)	Intact(S+)	6
Eroded(Mp)	Absent(I-)	Eroded(Sp)	4
Eroded(Mp)	Absent(I-)	Absent(Sp)	1
Eroded(Mp)	Eroded(Ip)	Intact(S+)	12
Eroded(Mp)	Eroded(Ip)	Eroded(Sp)	2
Total			145

*M+ = Malleus Intact, Mp = Malleus Partially Eroded, M- = Malleus Completed Eroded.

I+ = Incus Intact, Ip = Incus Partially Eroded, I - = Incus Completed Eroded. S+ = Stapes Intact, Sp = Stapes Partially Eroded, S- = Stapes Completely Eroded.

Table 4. Showing audiological profile of patients with ossicular chain disease.

Hearing loss intensity*	Total number of cases		Cases with OCD	
	Number	%	Number	%
Normal(<25)	2	1.38%	2	4.17%
Mild(26-40)	61	42.07%	7	14.58%
Moderate(41-55)	49	33.79%	15	31.25%
Mod to severe(56-70)	22	16.46%	13	27.09%
Severe(71-90)	7	5.65%	7	14.58%
Profound (90)	4	2.76%	4	8.33%
Total	145	100%	48	100%

Ossicular erosions are consistently seen in patients with squamosal disease, as well as in patients presenting with normal hearing and mild hearing loss (Table 5). It may be because of the presence of cholesteatoma, in which

the mass itself acts as a bridge for sound transmission in places where ossicular chain continuity is lost.

Table 5. Showing audiometric profile in mucosal and squamosal types.

Type of Hearingloss	Mucosal disease				Squamosal disease			
	N	%	Ossicular Erosions +	%	N	%	Ossicular Erosions +	%
Normal	---	---	---	---	2	1.38%	2	1.38%
Mild	54	47.37%	---	---	7	22.58%	7	22.58%
Moderate	34	29.83%	---	---	15	48.39%	15	48.39%
Mod to severe	18	15.15%	9	52.94%	4	8.06%	4	8.06%
Severe	5	4.03%	5	29.41%	2	1.61%	2	1.61%
Profound	3	2.07%	3	17.64%	1	0.69%	1	0.69%
Total	114	---	17	---	31	---	31	---

On further assessment with audiological profiling, mean pure tone audiometric (PTA) hearing loss was 45.84 dB. The mean hearing loss was higher (54.96 dB) in patients with ossicular erosion when compared with patients without ossicular erosion, who had a mean hearing loss of (41.30 dB). In our study, we predicted ossicular chain disease in 52 cases, out of which 42 cases showed ossicular erosions intraoperatively. 6 out of 93 cases which were not show any preoperative predictors signs showed ossicular erosions. (Table 6). We have predicted the presence of ossicular discontinuity with a sensitivity of 87.5%, specificity of 89.69%, and accuracy of 94.85%, while PPV and NPV are 80.76% and 93.54%, respectively. (Disease prevalence is 33.10%).

Table 6. Our prediction Vs. Ossicular chain disease.

		Intraop status showing ossicular chain status		
		OCD(+)	OCD(-)	Total
Prediction for ossicular erosion	OCD(+)	42	10	52
	OCD(-)	6	87	93
		48	97	145

4. Discussion

The age distribution of the patients ranged from more than 15 years to 60 years. The mean age of the study group patients was 46.8 years, and the majority of patients belonged to the 51-60 years age group, in contrast to various studies where the bulk of the study was done in younger age groups. Orji FT et al.^[11] concluded that COM affects the younger population with a mean age of 27.6. The prevalence of COM is higher in the older age group in our study area, which may be due to less awareness regarding health issues in the Chhattisgarh state population. Out of 145 patients, 52(35.86%) are males, and 93(64.14%) are female patients, showing a sex ratio of 1.71(F: M). A similar female preponderance was present in a study done by Jayakumar CL et al.^[12] and Pant S et al.^[13] whereas Albera R et al.^[14] showed male dominance in their study. In our study, 63 (43.45%) patients had left ear disease, 60

(41.38%) had right side disease, and bilateral disease was seen in 22 (15.17%) of total patients. Albera R et al.^[14] evaluated 66 right ears (47%) and 74 left ears (53%). Varshney S et al.^[15] also found similar results, with the right ear operated on in 78 (52.00%) cases and the left ear in 72 (48.00%) cases. Ear discharge (97.2%) and hearing loss (97.9%) were the most common complaints in our study. Other associated complaints, such as tinnitus (28.28%), ear pain (11.72%), and giddiness (13.1%), were also seen. In our study, one patient presented with complaints of facial weakness (0.69%). These results are comparable with findings in a study done by Pant S.,^[13] who showed the presence of tinnitus in 16% and ear pain in 6% of this study population. Previous studies by Binti Abdullah A et al.^[16] and Deshmukh S et al.^[17] also showed that hearing loss and ear discharge are common symptoms of COM. Our study showed that 28 (58.34%) out of 48 patients with diseased ossicles were presented with hearing loss ranging from moderate to moderately severe hearing loss. The more hearing loss in patients with ossicular erosion is statistically significant ($p < 0.001$) as compared to patients without ossicular erosion, similar to many recent studies.^[18-21] In cases of squamosal disease, only 50% of the patients presented with hearing loss ranging from moderately severe, severe, and profound loss, while 23.96% of patients detected with normal hearing or mild hearing loss showed ossicular erosions. This can be explained by the fact that pathological tissue can transmit sounds and replace damaged ossicles. Therefore, PTA could not be considered a precise predictor for ossicular erosion, especially in squamosal disease, due to the presence of cholesteatoma. Also, we found profound hearing loss in 4 of our patients due to more sensorineural hearing loss components, which may be due to noise-induced trauma, as Chhattisgarh, being an industrial area, was more prone to such cases. Diseased ossicles are consistently found in patients with higher hearing loss thresholds from moderately severe, severe, and profound hearing loss. By using spiral CT technology, a finite element model of the human ear was constructed. Numerical analysis is conducted and employed to predict the effects of middle ear cavity, malleus handle defect, hypoplasia of the long process of incus, and stapedia crus defect on sound transmission; and he concluded that ossicular erosions due to middle ear cavity disease showed decreased sound transmission.^[17] Mean pure tone audiometric (PTA) hearing loss was 45.84 dB. The mean hearing loss was higher, 54.96 dB, in patients with ossicular erosion when compared with patients without ossicular erosion, who had a

mean hearing loss of 41.30 dB. The difference (13.66 dB) significantly demonstrated that high hearing loss is an important predictor of ossicular necrosis in COM patients. Similar findings were observed in the study done by Jayakumar CL et al.^[12] and Pant S et al.^[13] This can be explained by a loss of ossicular coupling together with an enhancement of acoustic coupling of 10-20 dB as compared to the normal ear. The enhancement of acoustic coupling results from the loss of the shielding effect of the tympanic membrane, which in the normal ear attenuates middle ear sound pressure by 10-20 dB relative to ear canal sound pressure.^[6] As shown in many previous studies, Jayakumar CJ et al.,^[12] Pant S,^[13] and Alberta et al.^[14] presence of cholesteatoma is a significant risk factor for the presence of ossicular erosion. In our study, 21 out of 21(100%) cases with ossicular erosion had cholesteatoma in comparison to ossicular erosion without cholesteatoma, 27 out of 124 (21.77%) cases ($p < 0.001$). Thus, the presence of Cholesteatoma is a significant risk factor for ossicular erosion. We also found that 17 of the total 48 cases of ossicular erosions had mucosal disease. The propensity of ossicular erosions in squamous disease is due to the presence of cholesteatoma, block of aditus, and middle ear granulations. In cases of mucosal disease, long-standing perforation, with exposure to the incudostapedial joint and retracted tympanic membrane, can lead to ossicular erosion. According to a study done by Rout MR et al.,^[22] 74 cases out of 200 mucosal disease patients showed some amount of ossicular disease. Similar results were also seen in a study done by Varshney S et al.,^[15] who showed ossicular erosions in 6 cases out of 96 mucosal disease patients.

In our study, diseased ossicles were seen in 48 patients (33.10%) out of a total of 145 cases. Among the diseased ossicles, incus erosion was seen in 32.41%, followed by malleus erosions in 20.69%, and the least common erosions were seen in stapes (9.66%). Of these, incus was found to be the most commonly involved ossicle, with partial erosions seen in 29(20%) of cases, while completely eroded incus was seen in 18 (12.41%) of cases. Malleus was the next commonly involved ossicle, with partial erosions seen in 25 (17.24%) cases, and complete erosion was seen in 5 (3.45%) cases; less commonly involved ossicle was stapes, which was partially eroded in 13 (8.97%), and completely eroded in 1 case. Studies done by Albera R et al.,^[14] Varshney S et al.,^[15] and Arasan T et al.^[23] showed that erosions in stapes are more common than malleus. While in many studies, it was found that both malleus and incus could be equally affected.^[6, 18, 24] Thomsen J et al.^[25] observed that the Incus and superstructures of stapes were the most commonly involved ossicles where, as Feng X et al. noted that the frequency of involvement of ossicles was a long process of incus, crura of stapes, the body of incus, and manubrium of malleus.^[26]

We have documented ossicular chain erosions in a simpler format, and our results were comparable with those of a study by Arasan T et al.^[23] The Most common combination of multiple ossicular erosion in our study is M+IpS+, which was a similar finding in the classification proposed by Arasan T. We found in our study that moderate to severe type of hearing loss, air-bone gap (>40 dB), squamous active disease were the important positive predictors for ossicular chain discontinuity and by considering above parameters, we have predicted the presence of ossicular erosions in 52 cases; out of them 42 cases were found to have diseased ossicles intraoperatively. The negative prediction was made in 93 patients in whom 6 cases showed ossicular erosions intraoperatively. Thus, the prediction of the ossicular discontinuity in our study has a sensitivity of 87.5%, specificity of 89.69%, and accuracy of 94.85%. Many studies have been carried out in the past regarding ossicular chain status in cases of chronic otitis media and factors predicting ossicular disease preoperatively.^[17, 28] We have used the partially eroded ossicles for reconstruction, and the results are similar to those of the

prosthetic implants.^[29] However, ossicular reconstruction can be planned using the partially eroded ossicles or replacement prosthesis before proceeding to surgery after preoperative planning. The results are comparable to work done by Pant S et al.,^[13] who showed that long duration of the disease, moderate to severe hearing loss, subtotal perforation, air-bone gap >40 dB, presence of cholesteatoma and granulation tissue are the most important preoperative findings for the presence of ossicular erosion. According to Ebenezer J et al.,^[18] findings of active ear discharge ($P = 0.01$), anterosuperior location of perforation ($P = 0.03$), exposure of include-stapedial joint ($P = 0.05$), edematous middle ear mucous membrane ($P = 0.05$), middle ear granulations ($P = 0.004$), foreshortening of the handle of the malleus ($P = 0.04$), moderate to moderately severe hearing loss (41-70 dB HL) ($P = 0.000$), and air-bone gap > 40 dB ($P = 0.001$) were found to be associated with incus necrosis. Similar predictors were also studied by Jayakumar CJ,^[12] which showed that the presence of high ABG (>40db) and granulations in the middle ear cavity are high-risk factors for ossicular erosions.

5. Conclusion

Ossicular chain defects were intraoperatively found in both types of chronic otitis media but had more propensity for squamous disease. Other predictors for suspecting ossicular chain erosion include the longer duration of disease, high air-bone gap, and a high degree of hearing loss in patients of COM. So these factors help to consistently confirm the ossicular chain disease preoperatively; the pattern of ossicular erosion, which is most common, helps in better preparation for surgery as partially eroded ossicles can be used for ossicular reconstruction. The main limitation of this study is the lesser number of participants, the inclusion of patients of a higher age group, and the lack of follow-up on the outcome of ossicular reconstructed patients.

Conflict of Interest

The authors declared that there is no conflict of interest.

Acknowledgments

This research received no specific grant from any funding agency in the public, commercial, or not-for-profit sectors.

References

- [1] Acuin J. Geneva: World Health Organization; Global burden of disease due to chronic suppurative otitis media. Disease, deafness, deaths and DALYs Chronic Suppurative Otitis Media–Burden of Illness and Management Options. 2004:9-23.
- [2] Proctor B. The development of the middle ear spaces and their surgical significance. *The Journal of Laryngology & Otology*. 1964;78(7):631-45. <https://doi.org/10.1017/S002221510006254X>.
- [3] Browning GG, Weir J, Kelly G, Swan IR. Chronic otitis media. In Scott-Brown's Otorhinolaryngology and Head and Neck Surgery 2018;977-1019.
- [4] Horváth T, Lukács D, Horváth B, Ferenci T, Liktör B. Does the type of ossicular chain lesion affect outcomes in chronic suppurative otitis media without cholesteatoma?. *The Journal of International Advanced Otolaryngology*. 2019;15(1):28-33. <https://doi.org/10.5152/iao.2019.5554>.
- [5] Deka RC. Newer concepts of pathogenesis of middle ear cholesteatoma. *Indian J Otol*. 1998;4(2):55-7.
- [6] Sade J, Berco E, Buyanover D, Brown M. Ossicular damage in chronic middle ear inflammation. *Acta Oto-Laryngologica*. 1981;92(1-6):273-83. <https://doi.org/10.3109/00016488109133263>.

- [7] Bojrab DI, Balough BJ, Crane BT. Surgical anatomy of the temporal bone and dissection guide. *Glasscock-Shambaugh surgery of the ear*. 2003;5:778.
- [8] Merchant SN, Rosowski JJ. Conductive hearing loss caused by third-window lesions of the inner ear. *Otology & Neurotology*. 2008;29(3):282-9. <https://doi.org/10.1097/MAO.0b013e318161ab24>.
- [9] George GB, Merchant SN, Kelly G, Swan IR, Canter R, Mckerrow WSGleeson M. Chronic otitis media; Scott Brown's otorhinolaryngology, head and neck surgery. 2008;3:3395-401.
- [10] Wiatr A, Swiezy K, Skladzien J, Wiatr M. Scanning electron microscopy in the evaluation of defects to the ossicular chain in the course of chronic otitis media. *Ear, Nose & Throat Journal*. 2021;100(5):NP248-55. <https://doi.org/10.1177/0145561319873913>.
- [11] Orji FT, Ukaegbe O, Alex-Okoro J, Ofoegbu VC, Okorafor II. The changing epidemiological and complications profile of chronic suppurative otitis media in a developing country after two decades. *European Archives of Oto-Rhino-Laryngology*. 2016;273:2461-6. <https://doi.org/10.1007/s00405-015-3840-1>.
- [12] Jayakumar CL, Inbaraj LR, Pinto GJ. Pre-operative indicators of ossicular necrosis in tubotympanic CSOM. *Indian Journal of Otolaryngology and Head & Neck Surgery*. 2016;68:462-7. <https://doi.org/10.1007/s12070-016-0986-0>.
- [13] Pant S, Agarwal VK, Bist SS, Kumar L, Luthra M. Pre-Operative Predictors of Ossicular Status in Chronic Supportive Otitis Media. *Journal of Advanced Zoology*. 2023;44:12. <https://doi.org/10.17762/jaz.v44is-4.1506>.
- [14] Albera R, Canale A, Piumetto E, Lacilla M, Dagna F. Ossicular chain lesions in cholesteatoma. *Acta Otorhinolaryngologica Italica*. 2012;32(5):309-13.
- [15] Varshney S, Nangia A, Bist SS, Singh RK, Gupta N, Bhagat S. Ossicular chain status in chronic suppurative otitis media in adults. *Indian Journal of Otolaryngology and Head & Neck Surgery*. 2010;62:421-6. <https://doi.org/10.1007/s12070-010-0116-3>.
- [16] Binti Abdullah A, Hashim SM, Awang MA, Saim L. Outcome of canal wall down mastoidectomy: experience in sixty three cases. *Med J Malays*. 2013;68(3):217-21.
- [17] Deshmukh S, Sharma A, Dabholkar J. Mastoid cavity obliteration: our experience. *Otolaryngologia Polska*. 2012;66(6):379-81. <https://doi.org/10.1016/j.otpol.2012.08.001>.
- [18] Ebenezer J, Rupa V. Preoperative predictors of incudal necrosis in chronic suppurative otitis media. *Otolaryngology—Head and Neck Surgery*. 2010;142(3):415-20. <https://doi.org/10.1016/j.otohns.2009.11.026>.
- [19] Liu Y, Li S, Sun X. Numerical analysis of ossicular chain lesion of human ear. *Acta Mechanica Sinica*. 2009;25(2):241-7. <https://doi.org/10.1007/s10409-008-0206-6>.
- [20] Feng H, Chen Y, Ding Y. Analysis of preoperative findings and ossicular condition in chronic suppurative otitis media. *Journal of Clinical Otorhinolaryngology*. 2005;19(1):7-8.
- [21] Faramarzi M, Kazemi T, Roosta S, Faramarzi A, Naghmachi M. Is pre-operative audiometry a reliable predictor of ossicular chain condition? *American Journal of Otolaryngology*. 2023;44(5):103928. <https://doi.org/10.1016/j.amjoto.2023.103928>.
- [22] Rout MR, Das P, Mohanty D, Rao V, Susriitha K, Jyothi BE. Ossicular chain defects in safe type of chronic suppurative otitis media. *Indian Journal of Otology*. 2014;20(3):102-5. <https://doi.org/10.4103/0971-7749.136838>.
- [23] Arasan T. "New Classification of Ossicular Status" and Study In Patients with Ossicular Erosion to be Used for Ossiculoplasty. *Online Journal of Otolaryngology*. 2017;7(1).
- [24] Austin DF. Ossicular reconstruction. *Otolaryngologic Clinics of North America*. 1972;5(1):145-60. [https://doi.org/10.1016/S0030-6665\(20\)33024-3](https://doi.org/10.1016/S0030-6665(20)33024-3).
- [25] Thomsen J, Jorgensen MB, Bretlau P, Kristensen HK. Bone resorption in chronic otitis media. A histological and ultrastructural study I. Ossicular necrosis. *The Journal of Laryngology & Otology*. 1974;88(10):975-81. <https://doi.org/10.1017/S0022215100079639>.
- [26] Feng X, McDonald JM. Disorders of bone remodeling. *Annual Review of Pathology: Mechanisms of Disease*. 2011 Feb;6:121-45. <https://doi.org/10.1146/annurev-pathol-011110-130203>.
- [27] Kotzias SA, Seerig MM, Mello MF, Chueiri L, Jacques J, Silva MB, et al. Reconstrução da cadeia ossicular na otite média crônica: resultados auditivos e análise de fatores prognósticos. *Brazilian Journal of Otorhinolaryngology*. 2020;86:49-55. <https://doi.org/10.1016/j.bjorl.2018.09.005>.
- [28] Akarcay M, Kalcioğlu MT, Tuysuz O, Timurlenk E, Guclu H. Ossicular chain erosion in chronic otitis media patients with cholesteatoma or granulation tissue or without those: analysis of 915 cases. *European Archives of Oto-Rhino-Laryngology*. 2019;276:1301-5. <https://doi.org/10.1007/s00405-019-05339-2>.
- [29] Emami H, Shojasefat F, Moghtadaie A, Miratashi Yazdi SA, Jafari M. Incus Autograft Partial Ossicular Reconstruction Prosthesis vs. Titanium Angular Clip Prosthesis in Patients with Incudostapedial Joint Erosion Caused by Chronic Otitis Media; A Randomized Clinical Trial. *Indian Journal of Otolaryngology and Head & Neck Surgery*. 2022;1-5. <https://doi.org/10.1007/s12070-021-02605-w>.

How to Cite this Article: Ananthula M, Singh S. Preoperative Predictors and Ossicular Involvement in Chronic Otitis Media. *International Journal of Scientific Research in Dental and Medical Sciences*. 2024;6(1):1-6. <https://doi.org/10.30485/IJSRDMS.2024.434505.1554>.