



International Journal of Scientific Research in Dental and Medical Sciences

www.ijrdms.com



Hybrid Odontogenic Tumor with a unique presentation of the Calcifying Epithelial Odontogenic Tumor, Adenomatoid Odontogenic Tumor, and Calcifying Odontogenic Cyst: A Case Report

Nicolas Solano^a, Ligia Perez^b, Ejusmar Rivera^c, Carlos Medina^{c,*}

^a Department of Oral and Maxillofacial Surgery, School of Dentistry, University Hospital of Maracaibo, Zulia, Venezuela

^b Department of Oral and Maxillofacial Pathology, School of Dentistry, Emory University, USA

^c Department of Oral and Maxillofacial Surgery, School of Dentistry, La Universidad del Zulia, Venezuela

ARTICLE INFO

Article history:

Received 05 January 2021

Received in revised form 22 February 2021

Accepted 02 March 2021

Available online 11 March 2021

Keywords:

Adenomatoid Odontogenic Tumor

Calcifying Odontogenic Cyst

Odontogenic tumors

ABSTRACT

There are rarely hybrid neoplasms composed of two or more distinct histological types; a hybrid odontogenic tumor with a combination of the calcifying epithelial odontogenic tumor (CEOT) is present, adenomatoid odontogenic tumor (AOT) and calcifying odontogenic cyst (COC), located in the anterior mandible region from a 15-year-old male patient causing mild mobility of anterior mandible incisors with the labial and lingual expansion of the mandible cortical plates and obvious facial asymmetry. The tumor was surgically removed through an en-bloc resection approach. Microscopic examination revealed an atypical hybrid odontogenic tumor, with features of the three entities previously mentioned. Several cases of hybrid neoplasms have been reported in the literature. However, there is no evidence about the incidence of a hybrid odontogenic tumor with histologic features of CEOT combined with two other entities. In combination with COC, this is a unique presentation of a hybrid tumor not previously documented.

1. Introduction

Multiple odontogenic tumors may occur in a single patient, and also, a single odontogenic tumor with histopathological features of more than one of them can be present. In rare cases, hybrid neoplasms composed of 2 or more different histologic types occur, but their occurrence among odontogenic tumors has been relatively well recognized.^[1] These have been referred to as "hybrid" or "combined" lesions by other researchers. Their clinical presentations range from non-invasive cysts or hamartomas to benign and malignant neoplasms that vary greatly in their tendency for expansion and aggression.^[2] Recently, in 2017,^[3] the World Health Organization published its new classification of odontogenic tumors; nevertheless, there was no mention of this kind of unusual pathology. There are no reports in the literature of a hybrid tumor with these three entities' histopathological evidence. Therefore the objective of this article is to describe a unique presentation of the calcifying epithelial odontogenic tumor (CEOT), adenomatoid odontogenic tumor (AOT), and calcifying odontogenic cyst (COC).

2. Case Presentation

The University Hospital approved the present study of Maracaibo, Venezuela IRB, and all the participants signed an informed consent agreement. A 15-year-old male patient was referred to the Oral and Maxillofacial Surgery Service of University's Hospital of Maracaibo, Venezuela, to assess an asymptomatic swelling in the mental area with six months of evolution. Extraoral examination revealed a moderate indurated swelling on the chin, causing obvious facial asymmetry. Intraorally, mild mobility of anterior mandibular incisors with the labial and lingual expansion of the mandibular cortical plates was observed. Panoramic radiographic examination revealed a well-circumscribed radiolucent lesion with an irregular-shaped radiopaque image in the center, extended from the premolar area on the left side to the canine area on the right side. The four lower incisors presented radicular reabsorption (Fig. 1).

* Corresponding author. Carlos Medina

E-mail address: mdnacarlos@gmail.com

Department of Oral and Maxillofacial Surgery, School of Dentistry, La Universidad del Zulia, Venezuela

<http://doi.org/10.30485/IJSRDMS.2021.269482.1106>



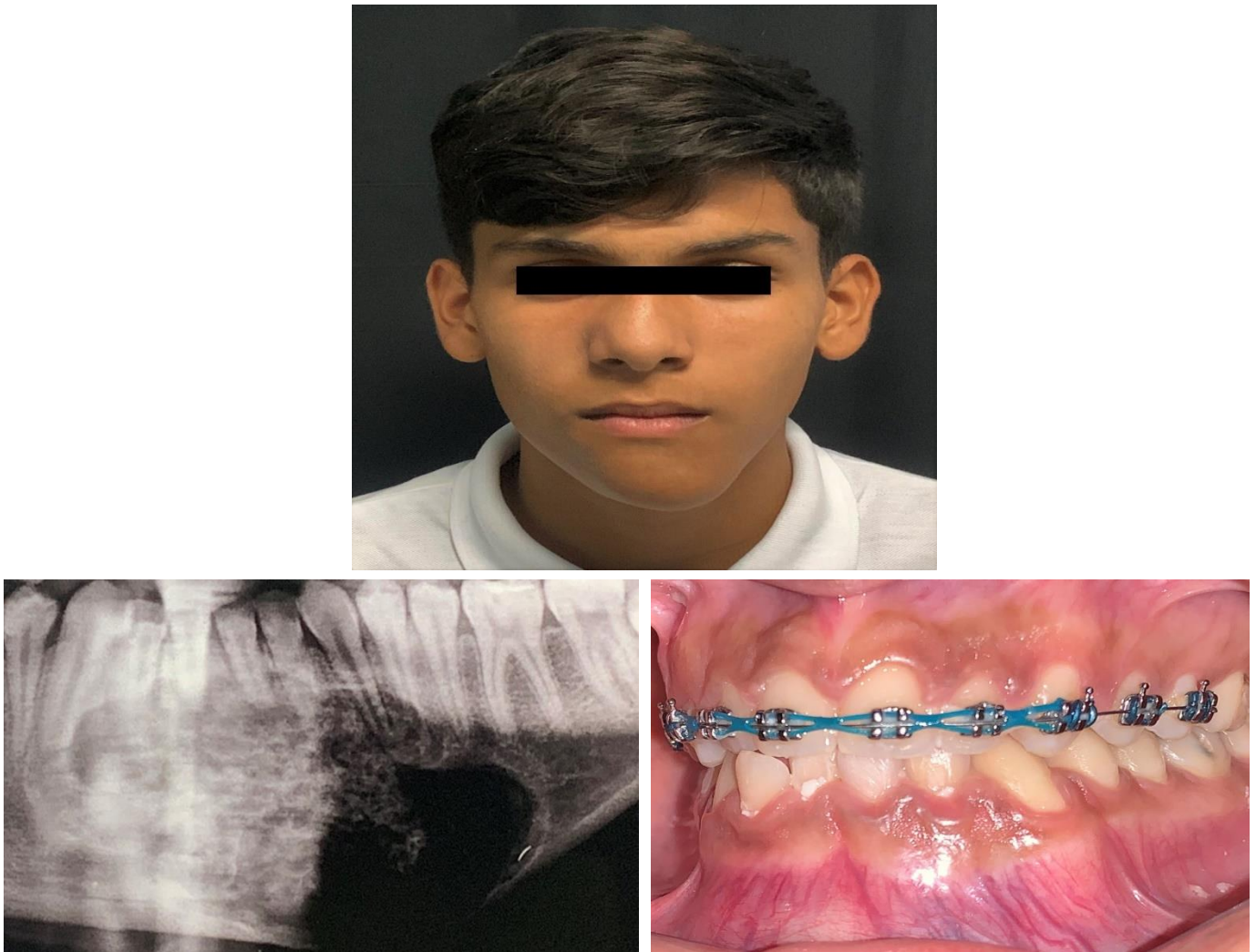


Fig. 1. (A) Extraoral photograph showing facial asymmetry. (B) Intraoral photograph showing buccal cortical plate expansion. (C) Panoramic radiography showing a radiolucent lesion in the anterior region of the mandible.

Computed tomography (CT) scan showed a unilocular isodense intraosseous mass, delimited by a hyperdense border with multiple hyperdense particles inside the lesion. The buccal and lingual bone plates

were perforated (Fig. 2). Differential diagnoses included central ossifying fibroma, calcifying odontogenic cyst, and adenomatoid odontogenic tumor.

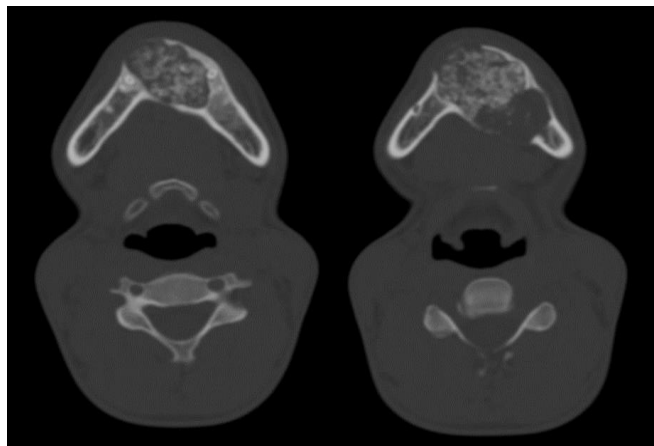


Fig. 2. Axial view of a computed tomography scan showing a unilocular isodense mass delimited by a hyperdense border with multiple hyperdense particles inside.

Incisional biopsy under local anesthesia was performed with the previous aspiration showing no evidence of any liquid substance, an envelope flap on the anterior region on the mandible was made, a tumor-like mass was observed with abundant crumbled bone, fragments were obtained and fixed in 10% formalin. The sample was sent to a microscopic examination where the sections showed fibrous connective tissue stroma with epithelial cells proliferation, some round, others oval, some with pleomorphic and

hyperchromatic nuclei and loss of nucleus-cytoplasm rate, organized in clusters, mostly large in some areas, in cords, or individually in others. Abundant calcified dental tissue was identified, in the form of trabeculae, with a dentinoid or cementoid appearance, in addition to rounded calcifications, with concentric basophilic lines. Occasional atypical mitotic figures were identified. The diagnosis of an atypical hybrid odontogenic tumor was obtained (Fig. 3).

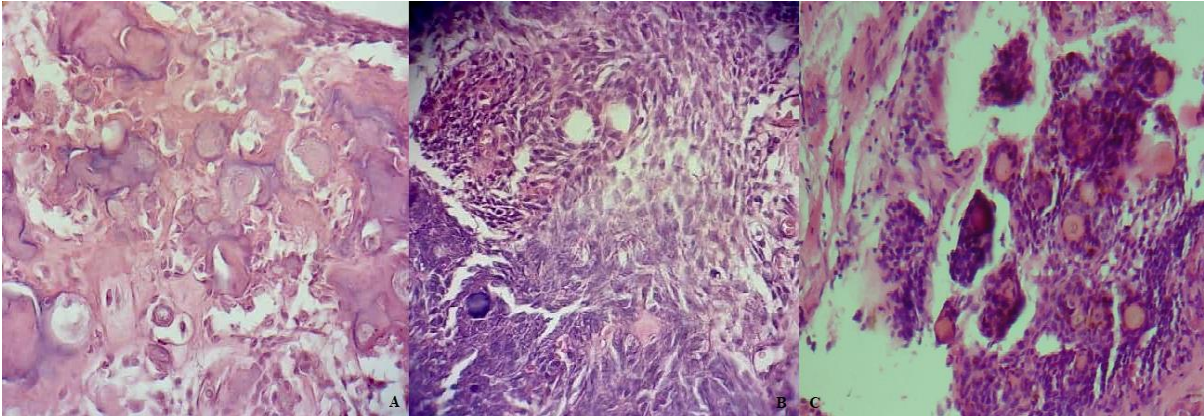


Fig. 3. (A) Hematoxylin and an eosin-stained section show round and polygonal cells, with some atypia, calcified material, as seen in the calcified epithelial odontogenic tumor (magnification x200). (B) Hematoxylin and an eosin-stained section show oval cells, organized concentrically, like adenomatoid odontogenic tumors (magnification x400). (C) Hematoxylin and an eosin-stained section show round hyalinized structures, associated with epithelial, oval, and Hyperchromatic cells, with ameloblastic aspect, consistent with calcified odontogenic cyst (magnification x100).

The patient was submitted to a surgical procedure under general anesthesia to remove the entire lesion. A bloc resection was performed from the left second molar to the right second premolar (Fig. 4), including an area

of 1 cm of bone beyond radiographical margins. A titanium plate was immediately placed, with no bone graft due to the lack of healthy soft tissue caused by the wide excision.

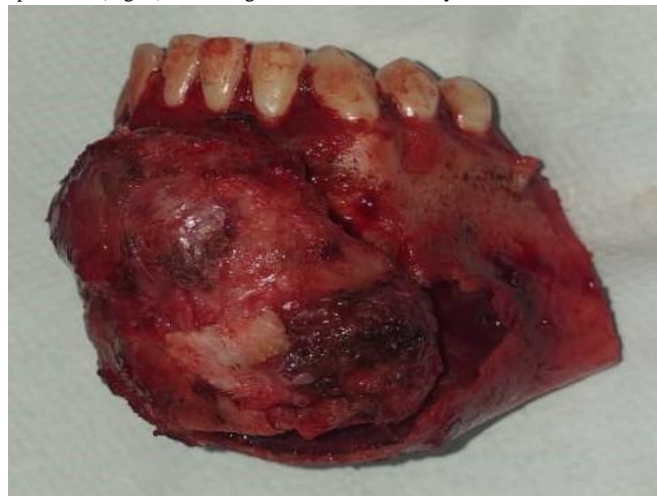

Fig 4. Surgical resection specimen.

The entire specimen was sent for histopathological analysis, and the sections corresponding to neoplastic soft and hard tissue showed fibrous connective tissue stroma, loose in some areas, dense in others, with hypercellular areas, consisting of small and oval cells with epithelial appearance, others with vesicular nuclei, some with pleomorphic and hyperchromatic nuclei, in addition to the loss of the nucleus-cytoplasm rate, organized in accumulations of varied shapes and sizes. Large areas of calcified, eosinophilic material with a dentinoid appearance were identified, while others were rounded, eosinophilic, and basophilic calcifications. Some of these structures resembled ghost cells. The diagnosis of an atypical hybrid

odontogenic tumor was confirmed. After six months of follow-up, the patient did not have any signs of recurrence; reconstructive surgery using bone transport distraction osteogenesis is planned.

3. Discussion

Due to multiple histopathological features in the lesion, a review of each entity described in this case is necessary. An uncommon odontogenic tumor arising from an odontogenic epithelium is a calcifying epithelial odontogenic tumor. CEOT presents a mixed radiographic appearance and frequently occurs in unerupted teeth associated with the posterior mandible.^[4] With a

peak incidence in the third and fourth decades of life, the tumor affects males and females equally and is considered a locally aggressive lesion, with malignant transformation reports.^[5] CEOTs are characterized by sheets of eosinophilic cytoplasm of the polygonal, pleomorphic epithelium, prominent intercellular bridging, and variable amounts of amyloid and concentric calcifications.^[6] The adenomatoid odontogenic tumor is a benign odontogenic tumor more prevalent in females, characterized by spindled shaped epithelial cells arranged in whorls or rosettes, duct-like structures, amyloid, and mineralization may be present in the second decade of life, in the anterior maxilla. AOTs are uncommon, benign, presenting as slow-growing, painless swellings characterized by indolent clinical behavior; they are amenable to simple curettage, with a low rate of recurrence, as well as encapsulated lesions.^[4, 6] Calcifying Odontogenic Cyst, previously named as calcifying cyst odontogenic tumor (CCOT), is an uncommon tumor with a developmental origin; an ameloblastoma-like epithelium with pale eosinophilic nucleate ghost cells that may calcify is more frequently reported in the maxillary anterior region of male predilection. COC shows variable clinical behavior and recurrence; this condition is therefore managed with a more extensive surgical approach than a simple curettage.^[4, 6]

Hybrid odontogenic neoplasms that present histopathologic features of 2 or more distinct odontogenic tumors are scarcely documented in the literature. Our case, the presentation is a combination of CEOT with AOT and COC, is a unique case not previously reported. Yamazaki et al.^[11] and their review of the literature of hybrid odontogenic tumors in 2014 found that the combination most frequently documented are CCOT+ odontoma, followed by CCOT + Ameloblastoma; they mention CCOT tends to be combined with various types of odontogenic tumors and just 2 of the cases reported contained three distinct histopathological types, as presented in our case. In addition to their review, the presence of CEOT is extremely rare. Only 3 cases in the English language have been reported, specifically 2 in combination with Ameloblastoma^[7, 8] and 1 with ameloblastic fibro-odontoma.^[9] In recent years, Wadhwanet al.^[10] reported a rare case of CEOT combined with Ameloblastoma, and Rathod et al.^[11] reported a case of CEOT combined with AOT. Garcia et al.^[12] 2016 presented a case of a hybrid odontogenic tumor composed of an AOT and CEOT. They showed a preview of the existing cases in the literature of this kind of combination; they found a total of 10 cases between the years 1983-1996^[13-20] but no incidence of a hybrid tumor with CEOT combined with two other entities, or even, no evidence of a combination with COC/CCOT. There is still controversy in the choice of surgical treatment for these neoplasms. In almost all the cases discussed, conservative surgical management by enucleation was the treatment used. However, in our case, the presence of a combination of 3 entities, the large extension and aggression of the tumor, and the atypical cell cytology, demanded a wide excision with evidence of lesion-free surgical margins.

4. Conclusion

Hybrid odontogenic neoplasms are rare, and the incidence of a combination of these three entities is a unique presentation reported in the literature. Due to the lack of evidence in the treatment of choice, the surgeons should base the management on the tumor's aggressiveness, possible recurrence, and histopathological findings. Long-term follow-up is remarkably necessary in all cases.

Conflict of Interest

The authors declared that there is no conflict of interest.

Acknowledgements

This research received no specific grant from any funding agency in the public, commercial, or not-for-profit sectors.

References

- [1] Yamazaki M, Maruyama S, Abé T, Babkair H, Fujita H, Takagi R, et al. Hybrid ameloblastoma and adenomatoid odontogenic tumor: report of a case and review of hybrid variations in the literature. *Oral surgery, oral medicine, oral pathology and oral radiology*. 2014;118(1):e12-8. <https://doi.org/10.1016/j.oooo.2013.08.032>.
- [2] Phillips MD, Closmann JJ, Baus MR, Torske KR, Williams SB. Hybrid odontogenic tumor with features of ameloblastic fibro-odontoma, calcifying odontogenic cyst, and adenomatoid odontogenic tumor: a case report and review of the literature. *Journal of oral and maxillofacial surgery*. 2010;68(2):470-4. DOI:<https://doi.org/10.1016/j.joms.2009.04.118>.
- [3] Wright JM, Vered M. Update from the 4th edition of the World Health Organization classification of head and neck tumours: odontogenic and maxillofacial bone tumors. *Head and neck pathology*. 2017;11(1):68-77. <https://doi.org/10.1007/s12105-017-0794-1>.
- [4] AB RS, Ogle OE. Odontogenic Tumors. *Dental Clinics of North America*. 2019;64(1):121-38. DOI: 10.1016/j.cden.2019.08.008.
- [5] Ibituruna AC, Costa AR, de Paulo LF, de Faria PR, Cardoso SV, Loyola AM. Multiple calcifying epithelial odontogenic tumor: case report and review of the literature. *Oral surgery, oral medicine, oral pathology and oral radiology*. 2019;128(3):268-72. <https://doi.org/10.1016/j.oooo.2019.03.018>.
- [6] Bilodeau EA, Seethala RR. Update on odontogenic tumors: proceedings of the North American Head and Neck Pathology Society. *Head and neck pathology*. 2019;13(3):457-65. <https://doi.org/10.1007/s12105-019-01013-5>.
- [7] Seim P, Regezi JA, O’Ryan F. Hybrid ameloblastoma and calcifying epithelial odontogenic tumor: case report. *Journal of oral and maxillofacial surgery*. 2005;63(6):852-5. DOI:<https://doi.org/10.1016/j.joms.2005.02.024>.
- [8] Eit D, Uyaroglu MA, Erdogan N. Mixed odontogenic tumor: Ameloblastoma and calcifying epithelial odontogenic tumor. *Indian Journal of Pathology and Microbiology*. 2010;53(1):122-124. DOI: 10.4103/0377-4929.59201.
- [9] Martin-Duverneuil N, Roisin-Chausson MH, Behin A, Favre-Dauvergne E, Chiras J. Combined benign odontogenic tumors: CT and MR findings and histomorphologic evaluation. *American journal of neuroradiology*. 2001;22(5):867-72.
- [10] Wadhwan V, Sharma P, Bansal V. A rare case of hybrid odontogenic tumor: Calcifying epithelial odontogenic tumor combined with ameloblastoma. *Journal of oral and maxillofacial pathology: JOMFP*. 2015;19(2):268. doi: 10.4103/0973-029X.164560.
- [11] Rathod V, Saluja S, Gondhalekar R, Pundir S, Dixit S, Agrawal S. Hybrid odontogenic lesion of the mandible: a rare case report with literature review. *International Journal of Oral-Medical Sciences*. 2014;12(4):245-50. <https://doi.org/10.5466/ijoms.12.245>.
- [12] Rosa AC, Soares AB, Furuse C, Lima SR, de Araújo VC, Passador-Santos F. A combined epithelial odontogenic tumor? A 7-year follow-up case. *Head and neck pathology*. 2017;11(4):519-24. <https://doi.org/10.1007/s12105-016-0767-9>.

- [13] Damm DD, White DK, Drummond JF, Poindexter JB, Henry BB. Combined epithelial odontogenic tumor: adenomatoid odontogenic tumor and calcifying epithelial odontogenic tumor. *Oral Surgery, Oral Medicine, Oral Pathology*. 1983;55(5):487-96. [https://doi.org/10.1016/0030-4220\(83\)90235-9](https://doi.org/10.1016/0030-4220(83)90235-9).
- [14] Bingham RA, Adrian JC. Combined epithelial odontogenic tumor—adenomatoid odontogenic tumor and calcifying epithelial odontogenic tumor: report of a case. *Journal of oral and maxillofacial surgery*. 1986;44(7):574-7. [https://doi.org/10.1016/S0278-2391\(86\)80101-X](https://doi.org/10.1016/S0278-2391(86)80101-X).
- [15] Siar CH, Ng KH. Combined calcifying epithelial odontogenic tumor and adenomatoid odontogenic tumor. *International journal of oral and maxillofacial surgery*. 1987;16(2):214-6. [https://doi.org/10.1016/S0901-5027\(87\)80133-9](https://doi.org/10.1016/S0901-5027(87)80133-9).
- [16] Okada Y, Mochizuki K, Sugimura M, Noda Y, Mori M. Odontogenic tumor with combined characteristics of adenomatoid odontogenic and calcifying epithelial odontogenic tumors. *Pathology, research and practice*. 1987;182(5):647-57.
- [17] Miyake M, Nagahata S, Nishihara J, Ohbayashi Y. Combined adenomatoid odontogenic tumor and calcifying epithelial odontogenic tumor: report of case and ultrastructural study. *Journal of oral and maxillofacial surgery*. 1996;54(6):788-93. [https://doi.org/10.1016/S0278-2391\(96\)90706-5](https://doi.org/10.1016/S0278-2391(96)90706-5).
- [18] Takeda Y, Kudo K. Adenomatoid odontogenic tumor associated with calcifying epithelial odontogenic tumor. *International journal of oral and maxillofacial surgery*. 1986;15(4):469-73. [https://doi.org/10.1016/S0300-9785\(86\)80040-0](https://doi.org/10.1016/S0300-9785(86)80040-0).
- [19] Siar CH, Ng KH. The combined epithelial odontogenic tumour in Malaysians. *British Journal of Oral and Maxillofacial Surgery*. 1991;29(2):106-9. [https://doi.org/10.1016/0266-4356\(91\)90093-K](https://doi.org/10.1016/0266-4356(91)90093-K).
- [20] Ledesma CM, Taylor AM, de León ER, de la Piedra Garza M, Jaukin PG, Robertson JP. Adenomatoid odontogenic tumour with features of calcifying epithelial odontogenic tumour.(The so-called combined epithelial odontogenic tumour.) Clinico-pathological report of 12 cases. *European Journal of Cancer Part B: Oral Oncology*. 1993;29(3):221-4. [https://doi.org/10.1016/0964-1955\(93\)90026-B](https://doi.org/10.1016/0964-1955(93)90026-B).

How to Cite this Article: Solano N, Perez L, Rivera E, Medina C. Hybrid Odontogenic Tumor with a Unique Presentation of the Calcifying Epithelial Odontogenic Tumor, Adenomatoid Odontogenic Tumor, and Calcifying Odontogenic Cyst: A Case Report. *International Journal of Scientific Research in Dental and Medical Sciences*, 2021;3(1):50-54. doi:10.30485/IJSRDMS.2021.269482.1106.